

Association between Retinal Morphology and Visual Functions in Eyes with Typical Neovascular Age Related Macular Degeneration: A Pilot Study

Rituparna Ghoshal, Ph.D.¹, Somnath Ghosh, Ph.D.², Sharanjeet Sharanjeet–Kaur, Ph.D.³,
Norliza Mohamad Fadzil, Ph.D.³, Nor Fariza Ngah, M.S.⁴

¹Department of Optometry, CT University, Ferozepur Rd, Sidhwan Khurd, Punjab 142024, India.

²Department of Allied Health Science and Technology, Kazi Nazrul University, Asansol, West Bengal 713340, India.

³Optometry and Vision Science Program, Faculty of Health Sciences, Universiti Kebangsaan Malaysia, Kuala Lumpur 50300, Malaysia.

⁴Department of Ophthalmology, Hospital Shah Alam, Shah Alam, Selangor 40000, Malaysia.

Received 25 January 2024 • Revised 11 February 2024 • Accepted 14 February 2024 • Published online 25 July 2024

Abstract:

Objective: The relationship between morphological and visual parameters in age-related macular degeneration may reveal markers for diagnosis and management of this disease. However, there is an insignificant paucity of research reporting any strong correlation between visual and morphological components of typical neovascular age-related macular degeneration (nAMD). Hence, the objectives of the present pilot research were to assess detailed visual components and various optical coherence tomography (OCT) parameters in eyes with typical nAMD, and to determine the association between them.

Material and Methods: Patients identified as naïve nAMD were recruited from a public hospital in Malaysia. Distance visual acuity (DVA), near visual acuity (NVA), reading speed (RS) and contrast sensitivity (CS) were assessed. Several quantitative and qualitative morphological parameters were evaluated, using the spectral-domain OCT.

Results: Fifteen newly diagnosed Typical nAMD eyes were examined. Mean (\pm standard deviation) DVA, NVA, CS and RS were recorded as: 0.92 ± 0.39 , 0.80 ± 0.38 , 0.75 ± 0.39 , 70.02 ± 14 , respectively. Average retinal thickness, central thickness and centre maximum thickness demonstrated good correlation ($r\geq 0.05$ with BCVA, NVA and CS. Similarly, the Centre minimum thickness demonstrated a good correlation ($r\geq 0.50$) with DVA. An intact external limiting membrane and photoreceptors inner and outer segment showed better visual components.

Contact: Rituparna Ghoshal, Ph.D.
Department of Optometry, CT University, Ferozepur Rd, Sidhwan Khurd, Punjab 142024, India.
E-mail: rituparna4ab@yahoo.co.in

J Health Sci Med Res 2024;42(6):e20241068
doi: 10.31584/jhsmr.20241068
www.jhsmr.org

© 2024 JHSMR. Hosted by Prince of Songkla University. All rights reserved.
This is an open access article under the CC BY-NC-ND license
(<http://www.jhsmr.org/index.php/jhsmr/about/editorialPolicies#openAccessPolicy>).

Conclusion: This present pilot study reported visual components and OCT parameters of Malaysian eyes with Typical nAMD, with some of the OCT parameters showing good correlation with visual components. Thus, regardless of its small sample size, this present pilot study generated new knowledge and understanding in this area. Future research with a larger sample is recommended.

Keywords: Malaysian eyes, neovascular age related macular degeneration, OCT parameters, visual components

Introduction

Neovascular age-related macular degeneration (nAMD) is a major cause of visual impairment among the elderly population. nAMD is characterized by choroidal neovascularization and its sequelae, such as haemorrhage, intraretinal or subretinal fluid, serous or hemorrhagic detachment of the sensory retina; with or without serous or hemorrhagic pigment epithelial detachment, and subretinal fibrosis without the presence of any other ocular pathology^{1,2}. Over the years nAMD has been divided into different subtypes- Typical nAMD, with different forms of choroidal neovascularisation (classic choroidal neovascularisation; occult choroidal neovascularisation or mixed choroidal neovascularisation), polypoidal choroidal vasculopathy (PCV) and retinal angiomatous proliferation³⁻⁷. Typical nAMD is more prevalent in Western countries; whereas, PCV is the most common subtype of nAMD in a majority of the Asian countries^{8,9}. Similar to other subtypes of neovascular AMD, Typical nAMD causes significant morphological changes leading to impairment of visual components. Previous research has reported the morphology and visual components of Typical nAMD in detail. However, reports on Malaysian Typical nAMD eyes are limited. Although the relationship between various retinal and visual components in Typical nAMD has been studied in several researches¹⁰⁻¹⁵, the correlation between retinal changes demonstrated by optical coherence tomography (OCT) and visual components may reveal suitable OCT and visual marker for typical

nAMD. Thus, they may help in detection, treatment and continuous monitoring of this chronic disease by identifying the most reliable OCT parameters and visual components representing the disease. However, the majority of the previous research reported a weak correlation between visual components and OCT markers in Typical nAMD; with a correlation coefficient ranging from 0.2 to 0.4. Therefore, the reported correlation failed to represent suitable OCT markers that can be useful in clinics. The possible reason could be the use of an automated grading system of OCT parameters or that it may only consider Snellen visual acuity as the visual component. Hence, the objectives of this present research were to evaluate visual components and retinal morphology of subjects with Typical nAMD, and to assess the association between them.

Material and Methods

This present pilot study was part of a longitudinal study that was conducted in the ophthalmology department of a tertiary public hospital in Malaysia to evaluate demography, visual components, quality of life and retinal morphology of different subtypes of AMD. From a total of 100 subjects with AMD, data of naive Typical nAMD individuals; aged 50 years and above, were included in this pilot study. Individuals with history of treatment including anti-vascular endothelial growth factor injection, photodynamic therapy, and/or laser treatment for Typical nAMD were excluded from the analysis.

Clinical procedure

I. Visual components

Several visual components, including distance and near visual acuity, Contrast sensitivity and reading speed, were assessed. A 4-meter Early Treatment Diabetic Retinopathy Study (ETDRS) Original Series Chart R from Goodlite was employed to measure the distance visual acuity (DVA). Subjects were asked to read every letter on the chart. Each correctly identified letter was allocated a value of 0.02 logMAR. When any subject was unable to read the top line at 4 meters, the test chart was moved to 3, 2 and 1 meters until the subject could read the top line. Conversion of DVA at a particular distance was performed. DVA was recorded in logMAR. A UiTM Malay-related word reading chart, developed to measure the reading performance of native Malay language speakers in clinical settings, was used in this study for recording near vision (NVA) and reading speed (RS). The reading chart was placed on a reading stand that was inclined at 45 degrees. A standard reading distance of 40 cms was maintained for all subjects. Subjects were asked to read loudly from the top line till they were no longer able to see a particular line or word. NVA was measured in logMAR as the smallest print size read¹⁶.

While recording the reading speed, the time taken to read the chart was noted using a stopwatch. It was noted in words per minute using the following formula: Reading Speed=total number of words read correctly/time taken to read the words X 60. Contrast sensitivity (CS) was measured using the Pelli-Robson chart at 1 meter. The chart was viewed monocularly at a distance of 1 meter through best correction. This Contrast score of the last triplet read was recorded¹⁷. As advised by the developer of the Pelli-Robson chart, an illumination of 85 candelas per square meter was kept while performing the contrast measurement.

II. Retinal morphology

The retinal morphology of all subjects was assessed using the spectral-domain OCT (Spectralis HRA+ OCT Heidelberg Engineering Inc, Heidelberg, Germany). A macular volume scan was performed in all eyes.

Image analysis

The association between the visual components and OCT parameters can only be measured once the parameters are assessed well; thus, evaluating the specific OCT parameters was of utmost importance. The automated segmentation of retinal layers and automated segregation of retinal layers can have errors, specifically in pathologies, wherein the software calliper often fails to recognize the RPE-BM junction and can mistake the outer segment of the photoreceptor as RPE. Hence, a semi-auto segmentation method was employed in this present study. Previous researches have justified the use of semi-auto segmentation in evaluating different OCT parameters in AMD eyes^{18,19}.

Qualitative and quantitative evaluation of OCT parameters at central 1 mm was done. At first, the green vertical marker, i.e., the software caliper, was placed at the foveal centre. Then, 1,000 micron around the fovea was selected. Selection of this 1,000 micron comprised of 500 micron on each side of the fovea: this was done manually. The qualitative parameters evaluated around the foveal of 1,000 micron (1 mm) are as follows: Integrity of the photoreceptors inner segment and outer segment junction, integrity of the external limiting membrane and the integrity of the retinal pigment epithelium-Bruch membrane complex were graded as: "present", "absent" or "discontinuous". "Present" indicated 75% or more of the parameters to be intact, "absent" indicated 25% or less than 25% of the parameters to be intact and "discontinuous" indicated more than 25% or less than 75% of the parameters being intact. The status of the external limiting membrane, the

photoreceptors inner segment and outer segment junction and the retinal pigment epithelium–Bruch membrane complex is shown in Figure 1.

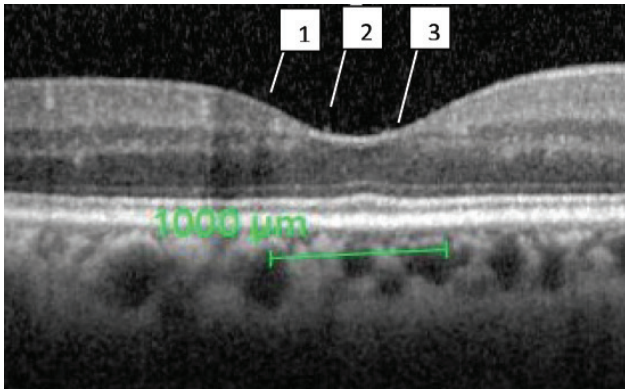
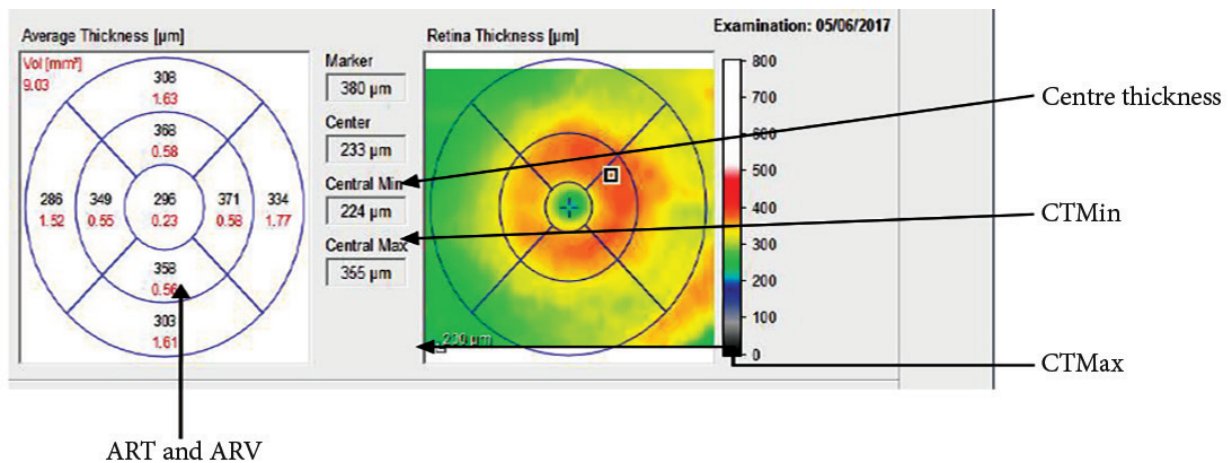


Figure 1 Selected 1,000 micron of fovea, with band 1 representing an external limiting membrane, band 2 representing the photoreceptors outer segment and inner segment junction, band 3 representing retinal pigment epithelium–Bruch membrane complex

Furthermore, quantitative parameters; including average retinal thickness and volume (ART & ARV), central retinal thickness (CT), centre maximum thickness (CTmax) and centre minimum thickness (CTmin), were measured on an OCT thickness map using the incorporated software of Spectralis OCT. At first the fovea was detected by the examiner. The caliper of the software was placed at the foveal central; hence, the green horizontal marker line was placed at the fovea. Then a 1, 3, 6 mm ETDRS grid was dragged until it coincided with the green horizontal line marker. Finally, the quantitative parameters of the centre 1 mm were recorded. (Note: 1, 3, 6 ETDRS grid measures 1, 3 and 6 mm of the retina). When measuring the thickness, the space between the internal limiting membrane and the Bruch membrane was considered. In study eyes, the upper marker is automatically placed at the outer border of the internal limiting membrane, while the lower marker is placed at the Bruch membrane. However, in some of the examined eyes having pigment epithelium detachment, the lower marker was automatically placed at the retinal pigment epithelium. In such cases, the lower marker was adjusted



ART and ARV

ART=average retinal thickness, ARV=average retinal volume, CTMin=centre minimum thickness, CTMax=centre maximum thickness

Figure 2 The software caliper is placed at the center of the fovea

and placed manually at the Bruch membrane line (Figure 2). In cases where the Bruch membrane line was missing, the marker was placed in consideration of an approximation for the Bruch membrane line.

Statistical analysis

Statistical analysis employed Statistical Package for the Social Science (SPSS) software (IMB SPSS 17; SPSS Inc. USA). Descriptive statistic was used to represent different study parameters. Independent t-test was employed to compare the visual components between groups, based on the status of qualitative OCT parameters; such as the integrity of photoreceptors inner segment and outer segment junction, the external limiting membrane and retinal pigment epithelium–Bruch membrane complex. Pearson's correlation was used to determine the association between different OCT parameters and visual components.

Results

There were 16 subjects with naive Typical nAMD. However, OCT of one subject was not available. Thus, 15 newly diagnosed Typical nAMD eyes from 15 participants, with a mean (standard deviation) age of 73.07 ± 7.86 years, were examined in this study.

I. Visual components

The majority of the eyes revealed moderate impairment in distance and NVA. Eight (8) eyes showed DVA worse than 0.5 to 1 logMAR; whereas, 5 eyes showed DVA worse than 1 logMAR. The average of the visual components of the study eyes are shown in Table 1.

II. Retinal morphology

Quantitative and qualitative measurements

In this present study, 10 subjects had the presence of sub-retinal fluid, 11 subjects had intra-retinal fluid and another 5 subjects showed sub-retinal fibrous

tissue. Retinal pigment epithelium detachments were seen in 7 subjects. Figure 3 (A to C) represents the different morphological characteristics of the study eyes. An external limiting membrane was present in 4 eyes, was discontinuous in 4 eyes and absent in 7 eyes. Similarly, the integrity of the photoreceptors inner segment and outer segment junction was noted as present, discontinuous and absent in 2, 5 and 8 eyes, respectively. The complex of the retinal pigment epithelium and Bruch membrane was reported as intact, discontinuous and absent in 6, 2 and 7 eyes, respectively. All quantitative parameters were varied in a wide range. Quantitative OCT markers of the study are described in Table 2. Figure 4 (A to C) shows the retinal thickness map of different Typical nAMD eyes; indicating notable thickening of different retinal areas.

Table 1 Description of visual components of Typical nAMD

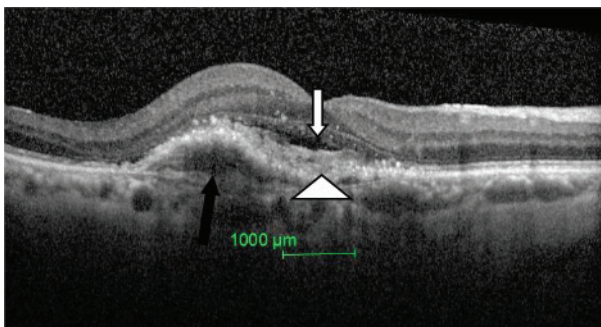
Parameters	Mean±S.D.	Minimum	Maximum
DVA (logMAR), n=15	0.92±0.39	0.14	1.30
NVA (logMAR), n=15	0.80±0.38	0.1	1.30
CS (log contrast), n=15	0.75±0.39	0.15	1.35
RS (words per minute), n=7	70.02±14	26	132

DVA=visual acuity, NVA=near visual acuity, CS=contrast sensitivity, RS=reading speed, S.D.=standard deviation, n=number of eyes

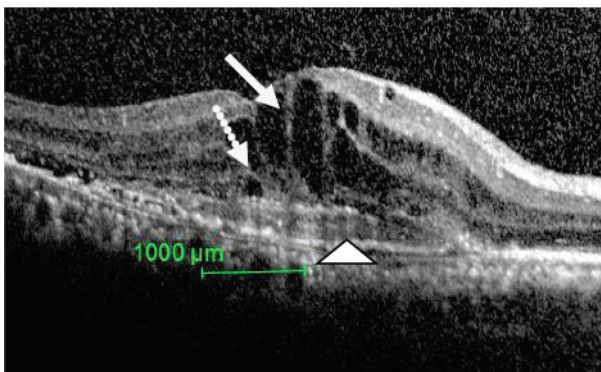
Table 2 Quantitative OCT parameters in Typical nAMD

OCT parameters (n=15)	Mean±S.D.	Maximum	Minimum
ART (micron)	499.86±149.09	752	300
ARV (mm ³)	0.42±0.10	0.59	0.24
CT (micron)	484.40±149.09	811	260
CTMax (micron)	642.666±195.26	873	408
CTMin (micron)	406.40±120.61	634	230

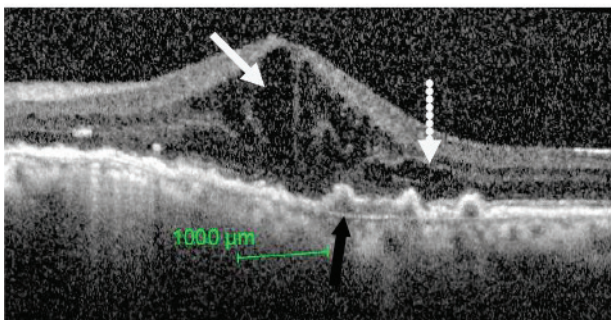
S.D.=standard deviation, n=number of eyes, ART=average retinal thickness, ARV=average retinal volume, CT=centre thickness, CTMax=centre maximum thickness, CTMin=centre minimum thickness



A

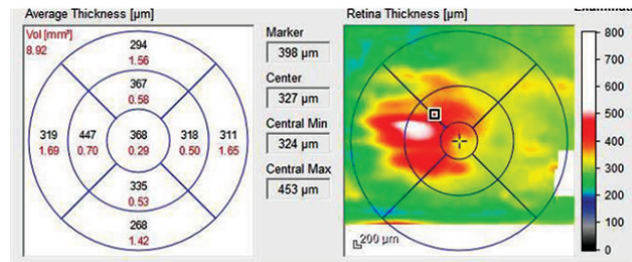


B

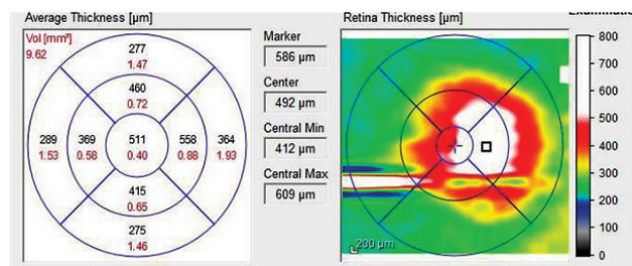


C

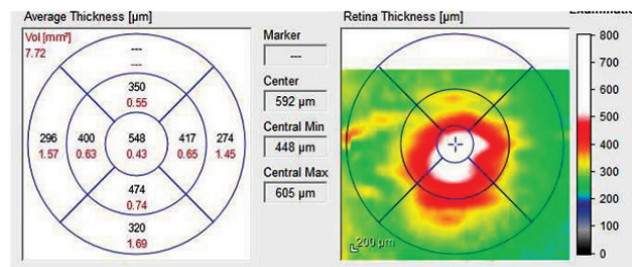
Figure 3 A: Sub retinal fluid (a small white arrow), sub retinal tissue (arrow head) and retinal pigment epithelium detachment (black arrow) are seen; B: Intra retinal fluid (white arrow), sub retinal fluid (dotted arrow) and sub retinal tissue (arrow head) are seen; C: Intra retinal fluid (white arrow), sub retinal fluid (dotted arrow) and small, bumpy retinal pigment epithelium detachments (black arrow) are seen.



A



B



C

Figure 4 (A–C) Retinal thicknesses map of Typical nAMD showing notable thickening in certain areas: displayed as hotter colours.

III. Correlation of visual components with quantitative retinal morphology parameters

DVA demonstrated a good correlation with ART, CT, CTMax and CTMin ($r > 0.5$). NVA showed a good correlation with ART, CT and CTMax ($r > 0.5$). CS demonstrated good correlation with ART, CT and CTMax. Table 3 shows the relationship between visual and quantitative retinal components of the study eyes. However, the association of OCT components with RS could not be analyzed, due to the small sample size.

IV. Association between visual components and qualitative retinal morphology parameters

Eyes where the external limiting membrane was present or discontinuous demonstrated a significantly better mean of all visual components (p-value<0.05) compared to those with an absent external limiting membrane. Similarly, eyes with intact photoreceptors inner segment and outer segment junction showed significantly better (p-value<0.05)

mean of all visual components compared to eyes where photoreceptors inner segment and outer segment junction were absent. Table 4 shows the relationship between the qualitative OCT parameters and visual components. However, the integrity of the complex of the retinal pigment epithelium and Bruch membrane showed no association with visual components (p-value>0.05).

Table 3 Relationship between visual components and quantitative retinal morphology parameters

Visual components	ART	ARV	CT	CTMax	CTMin
DVA	r=0.67 p=0.006	r=0.49 p=0.058	r=0.63 p=0.012	r=0.64 p=0.011	r=0.56 p=0.029
NVA	r=0.608 p=0.016	r=0.373 p=0.170	r=0.567 p=0.028	r=0.53 p=0.042	r=0.49 p=0.062
CS	r=-0.574 p=0.025	r=-0.333 p=0.225	r=-0.687 p=0.040	r=-0.59 p=0.047	r=-0.334 p=0.224

ART=average retinal thickness, ARV=average retinal volume, CT=centre thickness, CTMax=centre maximum thickness, CTMin=centre minimum thickness, DVA= distance visual acuity, NVA=near visual acuity, CS=contrast sensitivity, r=correlation coefficient, p-values that are statistically significant: p-value<0.05

Table 4 Association between visual components and qualitative OCT parameters

Visual components	Integrity of external limiting membrane		Integrity of inner segment and outer segment junction	
	Present/ discontinuous	Absent	Present/ discontinuous	Absent
DVA (n)	8	7	7	8
Mean±S.D.	0.68±0.37	1.1±0.16	0.63±0.38	1.1±0.17
t(df)		-3.273(13)		-3.55(13)
p-value		0.006		0.004
NVA (n)	8	7	7	8
Mean±S.D.	0.6±0.41	1.02±0.19	0.50±0.32	1.1±0.20
t(df)		-2.551(13)		-4.088(13)
p-value		0.026		0.001
CS (n)	8	7	7	8
Mean±S.D.	0.98±0.16	0.50±0.30	1.1±0.25	0.48±0.25
t(df)		2.897(13)		4.59(13)
p-value		0.012		0.001

DVA=visual acuity, NVA=near visual acuity, CS=contrast sensitivity, S.D.=standard deviation, n=number of eyes, t=t statistics, Df=degree of freedom, p-values that are statistically significant: p-value<0.05.

Discussion

This present study reported the retinal changes seen with OCT and detailed visual components of Malaysian eyes having Typical nAMD. More than half of the study eyes (53%) exhibited moderate visual impairment with DVA being <6/18 (0.5 logMAR) to 6/60 (1 logMAR); whereas 33% of the eyes had severe visual impairment having a best corrected distance vision worse than 6/60. Mean DVA of the evaluated eyes was 0.92 ± 0.39 logMAR. This is comparable to the findings of Cheung et al. (2014) that reported a mean DVA of 0.95 ± 0.55 logMAR in Typical nAMD eyes among Singaporeans²⁰. Similarly, Kashani et al. (2009) reported a mean distance vision of 0.77 ± 0.44 logMAR in 53 Typical nAMD eyes¹³. In contrast, Keane et al. (2010), Sho et al. (2001) and Ng et al. (2024) reported better DVA with a mean of 0.18 logMAR and 52.15 ± 11.62 letters and 0.46 logMAR, respectively^{14,21,22}. Differences between the study results could be due to differences of the study subjects disease duration, a potentially key determinant of visual components at presentation in patients with neovascular AMD. In addition, mean NVA and RS of the evaluated eyes that were measured with a UiTM Malay-related word reading chart were noted as 0.80 ± 0.38 logMAR and 70.02 ± 14 words per minute, respectively. This is similar to the findings of Keane et al. (2010) that reported a mean reading acuity of 0.89 ± 0.30 log reading acuity determination (RAD) in new Typical nAMD eyes. However, reports of RS of sole Typical nAMD eyes are limited¹⁴.

In this present study, the average CS of Typical nAMD eyes was reported as 0.75 ± 0.39 log contrast. Similarly, Keane et al. (2010) have reported a mean contrast of 0.84 ± 0.33 log contrast in 122 eyes with Typical nAMD¹⁴. Furthermore, all the study eyes exhibited a CS score of <1.65 log contrast. A CS score of 1.68 log contrast, using Pelli-Robson chart, for the age group of 60 years and above is considered as normal²³. This is similar to the research by Peterson et al. (2024) that reported a poor

mean CS score among AMD patients compared to healthy individuals²⁴. Hence, all the evaluated eyes of this present study had impaired CS; wherein all visual components of the study eyes showed significant impairment. This is in correspondence to the morphological changes seen in Typical nAMD eyes. In this present study, 10 subjects (60%) had the presence of sub-retinal fluid, 11 subjects (70%) had intra-retinal fluid and another 5 (33.33%) subjects showed sub-retinal fibrinous tissue. Retinal pigment epithelium detachments were seen in 7 (45%) eyes. Similarly, Keane et al. (2010) reported that 85% of neovascular AMD eyes showed sub-retinal fluid, 89% had sub-retinal tissue and 85% of the eyes had pigment epithelium detachment¹⁴.

This present study also evaluated and re-established the relationship between the visual components and quantitative and qualitative OCT parameters in Typical nAMD eyes. In correlation analysis, reporting correlation coefficient (*r*) is of utmost importance more so than reporting significance. Therefore, in spite of having a small sample, the results of the correlation found in this present study are worth reporting, as the strength of the correlation does not depend on the sample size. In this present study, ART, CT and CTMax demonstrated a good correlation ($r \geq 0.05$) with all the evaluated visual components. Similarly, CTMin demonstrated a good correlation ($r \geq 0.50$) with distance vision. This is comparable to the finding of Henschel et al. (2009) that found a significant association between decreased visual acuity with increased retinal thickness¹². Krebs et al. (2005) also reported a significant association between maximum retinal thickness and DVA²⁵. However, previous research on this reported a weak correlation between OCT parameters and visual components. OCT parameters, such as foveal thickness and total retinal thickness, were reported to have a correlation coefficient between 0.25 to 0.4. The reason behind a better correlation observed in this present study could be because it employs a semi-auto image analysis method, in which the examiner

manually adjusted the software caliper, selected the central 1,000 micron and adjusted both the upper and lower marker while measuring the thickness. Another reason could be the use of an logMAR chart following the developers instruction to report visual acuity. Each of the letters was given a value of 0.02. Thus, an accurate measurement of the visual acuity was performed; whereas, the majority of past studies used a Snellen visual acuity chart that has a test rest variability of almost 3 lines^{26,27}. Similarly, other visual parameters were measured by strictly following the developer's instruction, thereby providing an accurate estimate.

Furthermore, quantitative OCT parameters; including an intact external limiting membrane and photoreceptors inner and outer segment, showed better visual components. These included: DVA and NVA, and CS compared to those with an absent external limiting membrane and photoreceptors inner segment and outer segment junction. This is supported by the previous studies by Roberts et al. (2014) that reported a significant association between the integrity of photoreceptors inner segment and outer segment junction and best-corrected distance vision in nAMD patients²⁸. Similarly Fang et al. 2023 reported better continuity of an external limiting membrane and photoreceptors inner segment and outer segment junction of treated nAMD eyes²⁹. This result is well justified, as both an external limiting membrane as well as photoreceptors inner and outer segment junctions play an important role in photoreceptors function, and thereby their integrity is important in maintaining good visual components. A well-formed and confluent external limiting membrane is made up of junctional complexes between muller cells and photoreceptors³⁰. Hence, an external limiting membrane works as a connection between Muller cells and photoreceptors. Muller cells regulate neural activity by adjusting the extracellular concentration of neuro-active substances, thereby playing a significant role in retinal function³¹. Hence, a discontinuous or an absent external

limiting membrane indicates a distressed connection between Muller cells and photoreceptor, which may very much lead to photoreceptors malfunctioning, resulting in the impairment of several visual components.

Similarly, the photoreceptors inner segment and outer segment junction is made up of mitochondria within both the outer part of the photoreceptors inner segments^{30,32,33}. Thus, an intact junction of photoreceptors inner segment and outer segment indicates better function of photoreceptors, which is necessary to maintain good visual components.

However, the integrity of the complex for the retinal pigment epithelium and Bruch membrane did not show any correlation with visual components in this present study's eyes. This could be due to the fact that disruption of the complex for the retinal pigment epithelium and Bruch membrane may not necessarily affect the photoreceptors functions. This study's findings are similar to that of Keane et al. (2010), wherein they also did not find any relationship between pigment epithelium detachment and visual components in Typical nAMD eyes¹⁴.

Although, this present study evaluated the role of different quantitative and qualitative OCT parameters in the visual components of Typical nAMD, an increased sample size might have provided more information on this aspect.

Conclusion

This present pilot study reported visual components and OCT parameters of Malaysian eyes having typical nAMD. All the visual components of the study eyes showed significant impairment. OCT parameters, such as ART, CT and CTMax, demonstrated fair correlation with a majority of the visual components. Similarly, the integrity of an external limiting membrane and photoreceptors inner and outer segment junction were associated with better visual components. Thus, this present pilot study indicated that: if the visual and morphological components are measured accurately, there can be a fair correlation between them.

Therefore, future research with a larger sample size as well as additional qualitative and quantitative OCT parameters is recommended to procure suitable morphological and visual markers in eyes with Typical nAMD.

Ethical approvals

The ethics approvals were obtained from both the ethical committee of UKM (NN-099-2013) and MREC, Ministry of Health Malaysia (NMRR-13-346-16203).

Informed consent

Written informed consent was obtained from all patients.

Conflict of interest

The authors declare no conflicts of interest.

References

1. Coleman HR, Chan C, Ferris III FL, Chew EY. Age-related macular degeneration. *Lancet* 2008;372:1835–45.
2. The Royal College of Ophthalmologists. Age-related macular degeneration: guidelines for management. London: The Royal College of Ophthalmologists; 2013.
3. Maruko I, Iida T, Saito M, Nagayama D, Saito K. Clinical characteristics of exudative age-related macular degeneration in Japanese patients. *Am J Ophthalmol* 2007;144:15–22.
4. Takahashi K, Ishibashi T, Ogur Y, Yuzawa M. Working group for establishing diagnostic criteria for age-related macular degeneration. *Nippon Ganka Gakkai Zasshi* 2008;112:1076–84.
5. Yoshida Y, Kohno T, Yamamoto M, Yoneda T, Iwami H, Shiraki K. Two-year results of reduced-fluence photodynamic therapy combined with intravitreal ranibizumab for typical age-related macular degeneration and polypoidal choroidal vasculopathy. *Jpn J Ophthalmol* 2013;57:283–93.
6. Hata M, Tsujikawa A, Miyake M, Yamashiro K, Ooto S, Oishi A, et al. Two-year visual outcome of ranibizumab in typical neovascular age-related macular degeneration and polypoidal choroidal vasculopathy. *Graefes Arch Clin Exp Ophthalmol* 2015;253:221–7.
7. Sharanjeet-Kaur S, Ghoshal R, Fadzil N, Ghosh S, Aziz RABA, Ngah NF. Visual functions and retinal morphology in patients with polypoidal choroidal vasculopathy seen in an age-related macular degeneration referral centre of Malaysia. *Malays J Public Health Med* 2018;1:124–34.
8. Lim LS, Cheung CM, Wong TY. Asian age-related macular degeneration: current concepts and gaps in knowledge. *Asia Pac J Ophthalmol* 2013;2:32–41.
9. Ghoshal R, Sharanjeet-Kaur S, Fadzil N, Ghosh S, Ngah NF, Aziz RABA. Quality of life in patients with neovascular age related macular degeneration (n-AMD) seen in a public hospital of Malaysia. *Sains Malays* 2018;47:2447–54.
10. Keane PA, Liakopoulos S, Chang KT, Wang M, Dustin L, Walsh AC, et al. Relationship between optical coherence tomography retinal parameters and visual acuity in neovascular age-related macular degeneration. *Ophthalmology* 2008;115:2206–14.
11. Moutray T, Alarbi M, Mahon G, Stevenson M, Chakravarthy U. Relationships between clinical measures of visual function, fluorescein angiographic and optical coherence tomography features in patients with sub foveal choroidal neovascularisation. *Br J Ophthalmol* 2008;92:361–4.
12. Henschel A, Spital G, Lommatzsch A, Pauleikhoff D. Optical-coherence tomography in neovascular age related macular degeneration compared to fluorescein angiography and visual acuity. *Eur J Ophthalmol* 2009;19:831–5.
13. Kashani AH, Keane PA, Dustin L, Walsh AC, Sadda SR. Quantitative sub analysis of cystoid spaces and outer nuclear layer using optical coherence tomography in age-related macular degeneration. *Invest. Ophthalmol Vis Sci* 2009;50:3366–73.
14. Keane PA, Patel PJ, Ouyang Y, Chen FK, Ikeji F, Walsh AC, et al. Effects of retinal morphology on CS and reading ability in neovascular age-related macular degeneration. *Investig Ophthalmol Vis Sci* 2010;51:5431–7.
15. Pauleikhoff D, Gunnemann ML, Ziegler M, Heimes-Bussmann B, Bormann E, Bachmeier I, et al. Morphological changes of macular neovascularization during long-term anti-VEGF-therapy in neovascular age-related macular degeneration. *PLoS One* 2023;18:e0288861.
16. Buari NH, Chen AH, Musa N. Comparison of RS with 3 different log-scaled reading charts. *J Optom* 2014;7:210–6. doi: 10.1016/j.optom.2013.12.009.

17. Pelli DG, Robson JG, Wilkins AJ. The design of a new letter chart for measuring CS. *Clin Vis Sci* 1988;2:187–99.
18. Ghoshal R, Sharanjeet–Kaur S, Mohamad Fadzil N, Mutalib HA, Ghosh S, Ngah NF, et al. Correlation between visual functions and retinal morphology in eyes with early and intermediate age–related macular degeneration. *Int J Environ Res Public Health* 2020;17:6379.
19. Ghoshal R, Sharanjeet–Kaur S, Mohamad Fadzil N, Mutalib HA, Ghosh S, Ngah NF, et al. Visual parameters and retinal morphology for polypoidal choroidal vasculopathy pre– and post–intravitreal ranibizumab with or without photodynamic therapy: a short–term prospective study. *Int J Environ Res Public Health* 2021;18:2581.
20. Cheung CMG, Li X, Mathur R, Lee SY, Chan CM, Yeo I, et al. A prospective study of treatment patterns and 1–year outcome of asian age–related macular degeneration and polypoidal choroidal vasculopathy. *PLoS One* 2014;9:e101057.
21. Sho K, Takahashi K, Yamada H, Wada M, Nagai Y, Otsuji T, et al. Polypoidal choroidal vasculopathy: incidence, demographic features, and clinical characteristics. *Arch Ophthalmol* 2003; 121:1392–6.
22. Ng B, Kolli H, Ajith KN, Azzopardi M, Logeswaran A, Buensalido J, et al. Real–world data on faricimab switching in treatment–refractory neovascular age–related macular degeneration. *Life* 2024;14:193.
23. Mäntyjärvi M, Laitinen T. Normal values for the Pelli–Robson CS test. *J Cataract Refract Surg* 2001;27:261–6.
24. Peterson CL, Yap CL, Tan TF, Tan LY, Sim KT, Ong L, et al. Monocular and binocular visual function assessments and activities of daily living performance in age–related macular degeneration. *Ophthalmology Retina* 2024;8:32–41.
25. Krebs I, Binder S, Stolba U, Schmid K, Glittenberg C, Brannath W, et al. Optical coherence tomography guided retreatment of photodynamic therapy. *Br J Ophthalmol* 2005;89:1184–7.
26. Hogg RE, Chakravarthy U. Visual function and dysfunction in early and late age–related maculopathy. *Prog Retin Eye Res* 2006;25:249–76.
27. Falkenstein IA, Cochran DE, Azen SP, Dustin L, Tammewar AM, Kozak I, et al. Comparison of visual acuity in macular degeneration patients measured with Snellen and Early Treatment Diabetic Retinopathy Study charts. *Ophthalmology* 2008;115:319–23.
28. Roberts P, Mittermueller TJ, Montuoro A, Sulzbacher F, Munk M, Sacuet S, et al. A quantitative approach to identify morphological features relevant for visual function in ranibizumab therapy of neovascular AMD. *Invest Ophthalmol Vis Sci* 2014;55:6623–30.
29. Fang M, Chanwimol K, Maram J, Datoo O’Keefe GA, Wykoff CC, Sarraf D, et al. Morphological characteristics of eyes with neovascular age–related macular degeneration and good long–term visual outcomes after anti–VEGF therapy. *Br J Ophthalmol* 2023;107:399–405.
30. Spaide RF, Curcio CA. Anatomical correlates to the bands seen in the outer retina by optical coherence tomography: literature review and model. *Retina* 2011;31:1609–19.
31. Newman E, Reichenbach A. The Müller cell: a functional element of the retina. *Trends Neurosci* 1996;19:307–12.
32. Saxena S, Srivastav K, Cheung CM, Ng JYW, Lai TTY. Photoreceptor inner segment ellipsoid band integrity on spectral domain optical coherence tomography. *Clin Ophthalmol* 2014; 8:2507–22.
33. Narayan DS, Chidlow G, Wood JP, Casson RJ. Glucose metabolism in mammalian photoreceptor inner and outer segments. *Clin Exp Ophthalmol* 2017;45:730–741. doi: 10.1111/ceo.12952.