Original Article

JHSMR Journal of Health Science and Medical Research

Impact of Gross Classification on Outcomes of Chemoembolization for Hepatocellular Carcinoma

Panitpong Maroongroge, M.D.[1], Khemjira Vipasakulpit[2], Chutikan Sritongjoy[2], Tharanyaphat Sottibandhu[2], Pitchanan Saksakulchai[2], Ramida Thongsrisuk[2], Kitsarawut Khuancharee, Ph.D.[3], Apichart Thachang, M.D.[1], Wanaporn Burivong, M.D.[1], Asawin Soodcharoen, M.D.[4], Piyakorn Poonyam, M.D.[4], Piyanant Chonmaitree, M.D.[4]

[1]Department of Radiology, Faculty of Medicine, Srinakharinwirot University, Ongkharak, Nakhon Nayok 26120, Thailand.
[2]Medical Degree Program, Faculty of Medicine, Srinakharinwirot University, Ongkharak, Nakhon Nayok 26120, Thailand.
[3]Department of Preventive and Community Medicine, Faculty of Medicine, Srinakharinwirot University, Nakhon Nayok 26120, Thailand.
[4]Department of Medicine, Faculty of Medicine, Srinakharinwirot University, Nakhon Nayok 26120, Thailand.

Received 12 July 2025 ● Revised 27 January 2026 ● Accepted 27 February 2026 ● Published online 13 October 2026

Abstract:

Objective: This study investigated the effect of gross morphological classification, adhering to the Korean Liver Cancer Association (KLCA) guidelines, on chemoembolization efficacy in HCC patients.

Material and Methods: A retrospective analysis was conducted on HCC patients treated with TACE at HRH Princess Maha Chakri Sirindhorn Medical Center between January 2011 and August 2021. Gross morphology was categorized into six types, adapted from the KLCA guidelines: vague nodular (VN), expanding nodular (EN), multinodular confluent (MC), nodular with peri-nodular extension (NP), infiltrative (INF), and cirrhotomimetic (CM). For analysis, these were grouped into three categories: Group 1 (VN and EN), Group 2 (MC and NP), and Group 3 (INF and CM).

Results: A total of 132 patients were included in the study, with 41 (31.0%) in Group 1, 62 (47.0%) in Group 2, and 29 (22.0%) in Group 3. Patients with INF and CM morphology demonstrated the poorest prognosis, with a median survival of 0.87 years and a five-year survival rate of only 6.3%. Univariate analysis and multivariate analysis identified several prognostic factors associated with overall survival, including gross morphology, serum albumin level, and tumor burden.

Conclusion: Gross morphology and tumor burden are key prognostic indicators in patients undergoing TACE for HCC. Assessing gross morphology and tumor burden is essential for determining the suitability of TACE as a treatment option.

Contact: Piyanant Chonmaitree, M.D.
Department of Medicine, Faculty of Medicine, Srinakharinwirot University,
Ongkharak, Nakhon Nayok 26120, Thailand.
E-mail: piyanant_n@yahoo.co.th

J Health Sci Med Res
doi: 10.31584/jhsmr.20261455
www.jhsmr.org

© 2026 JHSMR. Hosted by Prince of Songkla University. All rights reserved.
This is an open access article under the CC BY-NC-ND license
(http://www.jhsmr.org/index.php/jhsmr/about/editorialPolicies#openAccessPolicy).

Keywords: gross morphology, HCC, TACE, tumor burden

Introduction

Transarterial chemoembolization (TACE) is the primary treatment for patients with intermediate-stage hepatocellular carcinoma (HCC). It's also an option for some early-stage HCC patients who are not candidates for other treatments, as well as for those with advanced-stage disease. There is growing evidence that the gross morphology of HCC may predict prognosis. The gross morphology of HCC can predict outcomes in patients undergoing resection, liver transplantation, and radiofrequency ablation (RFA)[1-8]. However, data on the impact of gross morphology in patients undergoing TACE remain limited. The Korean Liver Cancer Association (KLCA) classifies liver cancers into seven distinct groups[9]. This study aims to evaluate the impact of gross morphological classification, as defined by the KLCA guidelines, on chemoembolization outcomes in patients with HCC.

Material and Methods

Patient selection

This retrospective study analyzed data from the electronic medical records of patients newly diagnosed with HCC who underwent TACE as their primary treatment at the HRH Princess Maha Chakri Sirindhorn Medical Center in Nakhon Nayok, Thailand, between January 2011 and August 2021. All Thai patients diagnosed with HCC and treated with TACE were identified using the International Classification of Diseases 9th and 10th (ICD-9 and ICD-10) codes. HCC diagnosis was confirmed based on histological or radiological criteria following the European Association for the Study of the Liver (EASL) guidelines[10]. The exclusion criteria encompassed patients with hepatocholangiocarcinoma, those lacking pre-treatment imaging, and cases featuring incomplete clinical data or prior receipt of targeted therapy. Additional conditions warranting exclusion included extrahepatic spread, main portal vein invasion, previous bland embolization for a ruptured HCC, any ablation or resection following TACE, and the development of TACE refractoriness. Demographic and clinical information, including laboratory results and Child-Turcotte-Pugh (CTP) scores, were collected. Tumor characteristics, including size, type, number of nodules, and presence of segmental portal vein thrombosis (PVT), were assessed using computed tomography (CT) or magnetic resonance imaging (MRI). Disease staging was determined using the Barcelona Clinic Liver Cancer (BCLC) system. Tumor burden was calculated as the sum of tumor size and number of nodules in accordance with the Up-to-Seven criteria[11].

The interpretation of gross morphology was performed by two radiologists with more than 7 years of experience using categories adapted from the KLCA guidelines: vague nodular (VN), expanding nodular (EN), multinodular confluent (MC), nodular with peri-nodular extension (NP), infiltrative (INF), and cirrhotomimetic (CM) (Figure 1)[9]. The VN type is characterized by an enhancing nodule with an indistinct border. The EN type is defined as a round nodule surrounded by a pseudocapsule. The MC type describes a multinodular mass with confluent enhancement. The NP type presents as a mass exhibiting small extracapsular extension, typically observed at the anterior aspect. The INF type is a mass with extracapsular extension covering greater than 50% of the tumor circumference. The CM type consists of numerous nodules that are indistinguishable from liver cirrhosis on imaging. The pedunculated type was excluded from this study due to its rarity. In cases of disagreement, a third radiologist with more than 15 years of experience would provide the final assessment. To simplify classification,

HCC subtypes were grouped into three categories: Group 1 (VN and EN), Group 2 (MC and NP), and Group 3 (INF and CM). Dates of death were obtained from the Civil Registration Office. Overall survival was defined as the time from diagnosis to death or until January 1, 2023. This study was approved by the Ethics Committee of Srinakharinwirot University, Thailand (SWUEC/E-283/2564) and conducted in accordance with the Declaration of Helsinki.

Treatment protocol

TACE was performed via either the right common femoral or left radial artery approach. The celiac trunk and superior mesenteric artery were catheterized using a 5 Fr catheter to evaluate tumor location and blood supply. A microcatheter (1.98-2.8Fr) was advanced as selectively as possible into the tumor-feeding branch. Chemoembolization was performed using 10-20 mg of Mitomycin-C emulsified in iodized oil (Lipiodol® UltraFluid; Guerbet, Paris, France). The volume of iodized oil was determined based on tumor size, with a maximum volume of 15 cc per session. For patients with a large tumor burden and preserved liver function, an additional 500 mg of 5-Fluorouracil was slowly infused. Finally, absorbable gelatin sponge particles were administered until blood flow was completely occluded. Follow-up CT scans were performed 4-6 weeks after TACE. Residual viable lesions were retreated as needed. Patients were subsequently monitored with CT scans and serum alpha-fetoprotein (AFP) every 3-6 months, with additional treatments administered upon recurrence when feasible.

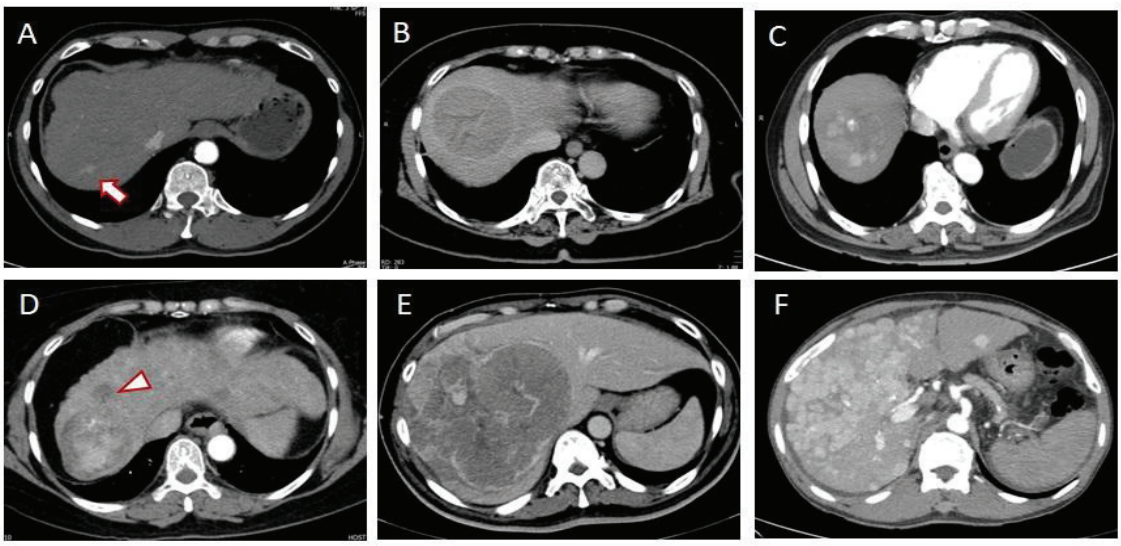

Figure 1 CT images of different classifications of hepatocellular carcinomas (A) Vaguely nodular (VN) type, an enhancing nodule in distinct border (arrow) (B) Expanding nodular (EN) type, a round nodule with pseudocapsule (C) Multinodular confluent (MC) type, a mass with multinodular enhancement (D) Nodular with perinodular extension (NP) type, a mass with small extracapsular extension at anterior aspect (arrowhead) (E) Infiltrative (INF) type, a mass with extracapsular extension greater than 50% of tumor circumference (F) Cirrhotomimetic (CM) type, numerous nodules that are unable to distinguish from liver cirrhosis

Statistical analysis

Statistical analyses were performed using STATA Version 14.0 (College Station, TX). Continuous variables were presented as mean±standard deviation (S.D.) or median (interquartile range) and compared using analysis of variance (ANOVA). Categorical variables were expressed as frequencies and percentages and analyzed using the Chi-square or Fisher's exact test. Overall survival across gross classification groups and the impact of variables on survival outcomes were analyzed using the Kaplan-Meier method and log-rank test. Prognostic factors were analyzed using Cox regression models for multivariate analysis. Variables were selected for inclusion in the multivariate model based on a p-value<0.2 in the univariate analysis or upon demonstrating clinical relevance. Statistical significance was set at p-value<0.05.

Results

A total of 260 HCC patients were assessed for eligibility. Exclusions were made for main portal vein thrombosis or extrahepatic spread (n=50), ruptured HCC (n=20), incomplete clinical data or lack of pre-treatment imaging (n=14), and receipt of other combined treatment modalities (n=44). Ultimately, 132 patients were included in the final analysis, with a predominance of male patients (81.8%).

The mean age of the study population was 59.6 years. The primary etiologies of HCC were hepatitis B virus (HBV) in 40.4%, alcohol in 40.2% and hepatitis C virus (HCV) in 31.8% of patients. Cirrhosis was present in 93.2% of cases, with 77.3% classified as CTP class A and 22.7% as CTP class B. The distribution of BCLC staging was as follows: very early stage (5.3%), early stage (39.4%), intermediate stage (43.2%), and advanced stage (12.1%). Single tumors were observed in 44.0% of patients, with most tumors (84.5%) measuring ≤10 cm. The gross classification of tumors included VN in 13.0%, EN in 18.0%, MC in 17.0%, NP in 30.0%, INF in 14.0%, and CM in 8.0% of cases. The intraclass correlation coefficient (ICC) for gross morphology assessment was 0.839 (95% CI: 0.788–0.889), indicating a high level of agreement between radiologists in assessing the gross morphology. When grouped into three broader categories, 31.0% of patients were classified as Group 1, 47.0% as Group 2, and 22.0% as Group 3. Additionally, 12.0% of patients had segmental PVT, and approximately 20.0% had AFP levels exceeding 1,000 IU/mL. A tumor burden of greater than 7 was observed in 47.0% of patients (Table 1). The BCLC staging, tumor size, presence of segmental PVT, AFP, and tumor burden significantly differed between the 3 groups (Table 1).

The median time from diagnosis to the initiation of TACE treatment was 1.23 months (95% CI=0.79–1.66). The median survival duration for HCC patients in this study was 2.15 years (95% CI: 1.47–2.97). When categorized by gross morphology, the median survival durations for Group 1, Group 2, and Group 3 were 3.30 years (95% CI: 1.83–4.55), 2.15 years (95% CI: 1.45–4.33), and 0.87 years (95% CI: 0.54–1.92), respectively. The one-year survival rates for Groups 1, 2, and 3 were 80.5% (95% CI: 64.75–89.73), 74.2% (95% CI: 61.38–83.32), and 48.3% (95% CI: 29.47–64.78), respectively. Correspondingly, the five-year survival rates were 24.2% (95% CI: 7.15–46.61), 32.5% (95% CI: 18.94–46.87), and 6.3% (95% CI: 3.70–27.69), respectively. Kaplan-Meier survival analysis demonstrated a statistically significant difference in survival outcomes among the three groups (p-value<0.001, log-rank test). Patients in Group 1 exhibited the longest survival duration, whereas those in Group 3 had the poorest prognosis (Figure 2).

Table 2 details the results of the survival analysis. Univariate analysis identified several factors significantly associated with overall survival: a tumor size greater than 10 cm (HR: 2.03, 95% CI: 1.10–3.72, p-value=0.02) and a tumor burden greater than 7 (HR: 2.40, 95% CI: 1.57–3.69, p-value<0.01), both of which were linked to decreased

Table 1 Baseline characteristics and clinicopathological features according to gross classification of HCC

Variable	Total (n=132)	Group 1 (n=41)	Group 2 (n=62)	Group 3 (n=29)	p-value
Age (years), Mean±S.D.	59.6±10.4	58.8±11.6	60.7±9.9	58.4±9.9	0.52[1]
Male, n (%)	108 (81.8)	32 (78.0)	50 (80.7)	26 (89.7)	0.45[2]
HCC Etiology, n (%)					
Hepatitis B	60 (40.4)	17 (41.2)	31 (50.0)	12 (41.4)	0.61[3]
Hepatitis C	42 (31.8)	16 (39.0)	18 (29.0)	8 (27.6)	0.49[3]
Alcohol	53 (40.2)	15 (36.6)	25 (40.3)	13 (44.8)	0.70[3]
NAFLD[†]	13 (9.9)	5 (12.5)	6 (9.7)	2 (6.9)	0.81[2]
Others	4 (3.0)	0	0	4 (13.8)	<0.01[2]
Hepatitis B + Hepatitis C	2 (1.5)	2 (4.9)	0	0	0.14[2]
Hepatitis B + Alcohol	19 (14.4)	4 (9.8)	11 (17.7)	4 (13.8)	0.59[2]
Hepatitis C + Alcohol	18 (13.6)	6 (14.6)	7 (11.3)	5 (17.2)	0.72[2]
Hepatitis B + Hepatitis C + Alcohol	1 (0.8)	1 (2.4)	0	0	0.53[2]
Hepatitis C + NAFLD[†]	1 (0.8)	1 (2.4)	0	0	0.53[2]
Hepatitis B + Alcohol + others	1 (0.8)	0	0	1 (3.4)	0.22[2]
Alcohol + NAFLD[†]	1 (0.76)	0	1 (1.6)	0	1.00[2]
Cirrhosis, n (%)	123 (93.2)	40 (97.6)	55 (88.7)	28 (96.6)	0.21[3]
CTP Class, n (%)					
A	102 (77.3)	34 (82.9)	46 (74.2)	22 (75.9)	0.57[3]
B	30 (22.7)	7 (17.1)	16 (25.8)	7 (24.14)	
BCLC staging[‡], n (%)					
Very early (0)	7 (5.3)	7 (17.1)	0	0	<0.01[2]
Early (A)	52 (39.4)	20 (48.8)	26 (41.9)	6 (20.7)	
Intermediate (B)	57 (43.2)	11 (26.8)	32 (51.6)	14 (48.3)	
Advanced (C)	16 (12.1)	3 (7.3)	4 (6.5)	9 (31.0)	
Tumor number, n (%)					
Single	58 (43.9)	21 (51.2)	28 (45.2)	9 (31.0)	0.09[2]
2	30 (23.4)	12 (29.3)	12 (19.4)	6 (20.7)	
3	14 (10.9)	2 (4.9)	10 (16.1)	2 (6.9)	
4–6	23 (18.0)	6 (14.6)	9 (14.5)	8 (27.6)	
≥7	7 (5.3)	0	3 (4.8)	4 (13.8)	
Tumor size >10 cm, n (%)	16 (15.5)	2 (4.9)	14 (22.6)	11 (37.9)	<0.01[2]
Segmental PVT, n (%)	16 (12.1)	2 (4.9)	4 (6.4)	10 (34.5)	<0.01[2]
Bilirubin >2 mg/dl, n (%)	1.1±0.6[¶]	4 (9.8)	7 (11.3)	1 (3.4)	0.54[2]
Albumin, g/dl					
>3.5	70 (53.0)	22 (53.7)	32 (51.6)	16 (55.2)	1.00[2]
2.8–3.5	45 (34.0)	14 (34.1)	22 (35.5)	9 (31.0)	
<2.8	17 (13.0)	5 (12.2)	8 (12.9)	4 (13.8)	
INR[§] >1.3, n (%)	1.2±0.1[¶]	8 (19.5)	13 (20.9)	7 (24.1)	0.90[3]
AFP[#] >1,000 IU/mL, n (%)	26 (19.8)	3 (7.5)	13 (20.9)	10 (34.5)	<0.01[2]
Tumor Burden >7, n (%)	64 (47.0)	9 (22.0)	34 (54.8)	19 (65.5)	<0.01[2]

*One patient had missing data, [¶]mean±S.D., [1]p-value from ANOVA, [2]p-value from Fisher's exact test, [3]p-value from Chi-square test, [†]NAFLD=nonalcoholic fatty liver disease, [‡]BCLC staging=Barcelona Clinic Liver Cancer staging, [§]INR=international normalized ratio, [#]AFP=alpha-fetoprotein, CTP=Child–Turcotte–Pugh

survival. Furthermore, serum albumin levels less than 2.8 g/dL were associated with significantly reduced survival (HR: 2.77, 95% CI: 1.33–5.77, p-value<0.01). In contrast, BCLC Stage A showed a trend toward better survival, although it did not reach statistical significance (HR: 0.37, 95% CI: 0.13–1.11, p-value=0.08). Similarly, potential associations with poorer outcomes were observed in patients with Group 3 morphology (HR: 1.89, 95% CI: 0.97–3.70, p-value=0.06) and those with serum bilirubin levels of 2–3 mg/dL (HR: 2.00, 95% CI: 0.94–4.29, p-value=0.07). These variables were included in the multivariate model based on their clinical relevance or a univariate p-value<0.2. Following the multicollinearity test, tumor size and tumor burden were found to be highly correlated. Consequently, tumor burden was included in the final model.

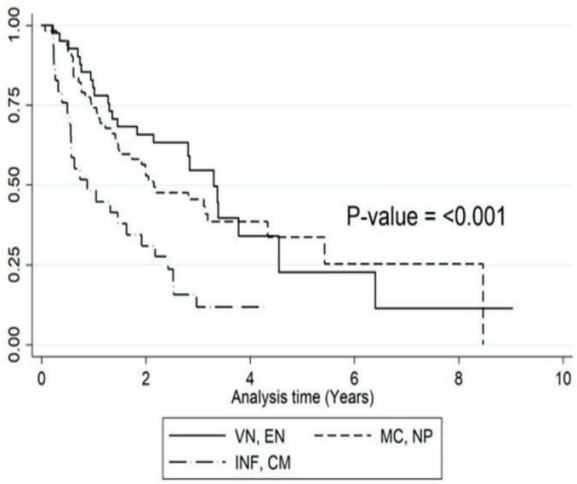

Figure 2 Kaplan-Meier curves of overall survival according to gross morphology

Table 2 Survival analysis

Variable	Overall survival			
	Univariate analysis		Multivariate analysis	
	HR (95% CI)	p-value	AHR (95% CI)	p-value
Age	1.00 (0.97-1.02)	0.72	0.99 (0.97-1.02)	0.49
Female	0.71 (0.37-1.37)	0.31	0.71 (0.37-1.37)	0.31
BCLC staging*				
A	0.37 (0.13-1.11)	0.08	0.36 (0.12-1.09)	0.07
B	0.47 (0.15-1.45)	0.19	0.42 (0.14-1.30)	0.13
C	0.99 (0.28-3.46)	0.99	0.86 (0.24-3.04)	0.81
Tumor size >10 cm.	2.03 (1.10-3.72)	0.02	NA†	
Gross morphology				
Group 2	0.78 (0.43-1.43)	0.42	0.80 (0.44-1.45)	0.46
Group 3	1.89 (0.97-3.70)	0.06	1.92 (1.00-3.69)	0.05
Total bilirubin 2-3 mg/dl	2.00 (0.94-4.29)	0.07	1.61 (0.74-3.53)	0.23
Albumin				
2.8-3.5 g/dl	1.65 (0.99-2.76)	0.05	2.01 (1.19-3.41)	<0.01
<2.8 g/dl	2.77 (1.33-5.77)	<0.01	2.92 (1.35-6.32)	<0.01
Tumor burden >7	2.40 (1.57-3.69)	<0.01	2.73 (1.52-4.92)	<0.01

*BCLC staging, Barcelona Clinic Liver Cancer staging, †NA, not assessed, ‡exact p-value=0.049 report as 0.05 due to rounding, Global test=0.8572, Harrell's C concordance statistic=0.7309 (95% CI 0.6867-0.7750), HR=hazard ratio, AHR=adjusted hazard ratio, CI=confidence interval

In multivariate analysis, gross morphology, serum albumin level, and tumor burden remained significant predictors of overall survival. Group 3 morphology remained an independent risk factor for mortality (AHR: 1.92, 95% CI: 1.00–3.69, p-value=0.049). Low albumin levels were associated with a significantly worse prognosis, with an AHR of 2.01 (95% CI: 1.19–3.41, p-value<0.01) for albumin levels of 2.8–3.5 g/dL and an AHR of 2.92 (95% CI: 1.35–6.32, p-value<0.01) for levels less than 2.8 g/dL. High tumor burden (greater than 7) also remained an independent predictor of mortality (AHR: 2.73, 95% CI: 1.52–4.92, p-value<0.01). The global test for the proportional hazard assumption yielded a p-value of 0.8572.

Discussion

There are several classifications of the gross morphology of HCC. Eggle's classification categorizes HCC into nodular, massive, and diffuse types. However, since the specimens were collected from autopsies, assessing early-stage tumors is limited. The Liver Cancer Study Group of Japan (LCSGJ)[12,13] proposed a classification with four types: single nodular (SN), single nodular with extra-nodular growth (SNEG), confluent multinodular (CMN), and infiltrative (IFN). The CMN and IFN groups of the LCSGJ classification exhibited greater vascular invasion, poor differentiation histology, higher recurrence rate, and lower survival compared to the SN and SNEG groups[3,7,8,14]. The SN group had lower rates of portal vein invasion and intrahepatic metastasis, fewer satellite lesions, a lower recurrence rate, and higher disease-specific survival than the SNEG and CMN groups. Additionally, the SNEG and CMN groups had lower E-cadherin expression than the SN group[15]. E-cadherin is a cell adhesion molecule expressed by epithelial cells. Reduced E-cadherin expression correlated with poor overall survival and recurrence-free survival[16]. The IFN group demonstrated enhanced angiogenesis and immune scores, reduced metabolic pathways and lipid transport, and exhibited the highest frequency of TP53 mutations[3].

According to the KLCA classification, the MC, NP, and INF groups demonstrated significantly lower overall survival and disease-free survival rates, along with higher rates of larger size, vascular invasion, and poorer histological differentiation, compared to the VN and EN groups[8]. The MC, NP, and INF types exhibited higher levels of Keratin 19 (K19) and the epithelial cell adhesion molecule (EpCAM), both markers of stem cell properties[8]. EpCAM, a transmembrane glycoprotein, plays a crucial role in cell signaling, proliferation, differentiation, and the formation and maintenance of organ morphology. When combined with AFP, EpCAM predicts the prognosis of HCC and serves as a biomarker for chemoresistance in HCC. The EN and VN groups demonstrated significantly better disease-free survival and overall survival than other groups when undergoing narrow resection margins[6]. The IFN group had a higher expression of summed stemness-related markers (CD24, CD44, CD133, SALL4, YAP1, K19, and EpCAM) and hypoxic/fibrotic tumor microenvironment (TME)[17]. A significant alteration in the tumor microenvironment (TME) is proposed as the explanation for these findings. Increased expression of β-catenin and matrix metalloproteinase 9 (MMP-9), and decreased expression of E-cadherin, were observed in the resection margins of the EN and VN groups. Additionally, significant changes in β-catenin and MMP-9 expression were noted from HCC tissue to adjacent normal tissue in these groups[6]. β-catenin functions as an intracellular signal transducer in the Wnt signaling pathway, frequently upregulated in HCC. MMP-9 plays a crucial role in extracellular matrix remodeling and angiogenesis. Its expression is linked to significant portal vein invasion and serves as a predictor for overall survival rates and recurrence following resection and liver transplantation[18,19].

There was a lack of data regarding the impact of gross pathology on the prognosis of HCC patients treated

with TACE. Nevertheless, a study examining the gross pathology of HCC patients who underwent TACE found that non-nodular HCC exhibited a lower objective radiological response rate, a shorter time to progression, and a worse prognosis[20]. Non-nodular HCC was characterized as one or several irregularly shaped tumors, or lobulated tumors with focal or multifocal outgrowths of nodules protruding into non-tumor parenchyma, as seen on axial, coronal, and sagittal imaging. The SN group had better efficacy, assessed by the tumors' necrotic to liver cell ratio after TACE[21]. In patients with HCC who underwent partial hepatectomy, the efficacy of TACE was highest in those with SN or SNEG[21]. Encapsulated nodular type HCC tends to respond better to TACE than other morphological types like extranodular, confluent multinodular, and infiltrative types[22]. To date, no study has utilized the KLCA gross morphology classification to predict prognosis in patients treated with TACE. Our study addresses this critical gap, revealing a poorer prognosis for TACE-treated patients in Group 3 (INF and CM) compared to those in Group 1 (VN and EN) and Group 2 (MC and NP). Nevertheless, this result was borderline significant (p-value=0.049); the finding should be interpreted with caution and requires validation in future, larger-scale studies. This conclusion is consistent with updated BCLC guidelines, which recommend targeted therapy instead of TACE for cases involving diffuse, infiltrative, extensive, or bilobar disease. Additionally, the Asia-Pacific Primary Liver Cancer Expert (APPLE) and Japan Society of Hepatology (JSH) consensus reports already suggest that patients with certain high-risk subtypes (including INF) are unlikely to benefit from TACE. Our results provide robust, supporting evidence that TACE is unsuitable for INF and CM cases and that targeted therapy should be prioritized for these specific tumor morphologies.

The Up-to-Seven criteria are well-known for describing tumor burden and were utilized to identify patients likely to experience TACE failure or refractoriness, according to the APPLE consensus and the JSH consensus[23,24]. In our study, 60.0% of Group 1 and about 35.0% of Group 3 exhibited a tumor burden of less than 7. The discrepancy in tumor burden between the gross morphology groups was statistically significant. Tumor burden serves as a predictor of survival in HCC patients treated with TACE.

The interpretations of our results should be made within the context of several noteworthy limitations. First, the retrospective design of the study inherently introduces the possibility of selection bias, which potentially restricts the external validity and generalizability of the findings. Second, a significant constraint is the lack of direct pathological validation. Specifically, we were unable to establish a formal histopathological correlation between the imaging-based assessment of gross tumor morphology and the eventual pathology of the final surgical specimen. Furthermore, the small sample size of our cohort, especially the notably limited number of cases in the CM group, substantially restricts the statistical power and broader applicability of our conclusions. We also acknowledge a methodological limitation: the three-group categorization of gross morphology served as an initial investigative framework and is not yet supported by established clinical or pathological consensus. Lastly, two data-related issues must be considered: the absence of detailed information regarding TACE (transarterial chemoembolization) session frequency and patient refractoriness, and the inherent potential for measurement imprecision in recorded tumor dimensions, particularly for the more morphologically complex CM and INF types. Future multi-center studies with larger cohorts are needed to confirm these results and improve their applicability.

Conclusion

This study provides comprehensive insights into the prognostic factors influencing survival outcomes in HCC patients. The median survival duration was 2.15

years, with significant differences observed across tumor morphology groups. Patients with Group 3 demonstrated the poorest prognosis. Gross morphology, serum albumin level, and tumor burden were identified as independent predictors of survival. These findings highlight the prognostic implications of tumor burden and gross morphology in HCC. Stratification of patients based on these factors may improve risk assessment and guide clinical decision-making. Future studies should further investigate the biological mechanisms underlying these associations and explore potential therapeutic interventions tailored to high-risk patient subgroups.

Conflict of interest

None.

References

1. Xu XF, Wu H, Li JD, Yao LQ, Huang B, Diao YK, et al. Association of tumor morphology with long-term prognosis after liver resection for patients with a solitary huge hepatocellular carcinoma-a multicenter propensity score matching analysis. Hepatobiliary Surg Nutr 2023;12:314-27.
2. Fu X, Mao L, Tang M, Yan X, Qiu Y, He J, et al. Gross classification of solitary small hepatocellular carcinoma on preoperative computed tomography: Prognostic significance after radiofrequency ablation. Hepatology Research 2016;46:298-305.
3. Fan Z, Jin M, Zhang L, Wang N, Li M, Wang C, et al. From clinical variables to multiomics analysis: a margin morphology-based gross classification system for hepatocellular carcinoma stratification. Gut 2023;72:2149-63.
4. Shimada M, Rikimaru T, Hamatsu T, Yamashita Y, Terashi T, Taguchi K, et al. The role of macroscopic classification in nodular-type hepatocellular carcinoma. Am J Surg 2001;182:177-82.
5. Murakata A, Tanaka S, Mogushi K, Yasen M, Noguchi N, Irie T, et al. Gene expression signature of the gross morphology in hepatocellular carcinoma. Ann Surg 2011;253:94-100.
6. Cha SW, Sohn JH, Kim SH, Kim YT, Kang SH, Cho MY, et al. Interaction between the tumor microenvironment and resection margin in different gross types of hepatocellular carcinoma. J Gastroenterol Hepatol 2020;35:648-53.
7. He J, Shi J, Fu X, Mao L, Zhou T, Qiu Y, et al. The Clinicopathologic and Prognostic Significance of Gross Classification on Solitary Hepatocellular Carcinoma After Hepatectomy. Medicine 2015;94:e1331.
8. Lee Y, Park H, Lee H, Cho JY, Yoon YS, Choi YR, et al. The Clinicopathological and Prognostic Significance of the Gross Classification of Hepatocellular Carcinoma. J Pathol Transl Med 2018;52:85-92.
9. Jang J, Lee J, Kim H-J, Shim J, Kim jh, Kim B, et al. The General Rules for the Study of Primary Liver Cancer. J Liver Cancer 2017;17:19-44.
10. Reig M, Forner A, Rimola J, Ferrer-Fàbrega J, Burrel M, Garcia-Criado Á, et al. BCLC strategy for prognosis prediction and treatment recommendation: The 2022 update. J Hepatol 2022;76:681-93.
11. Mazzaferro V, Llovet JM, Miceli R, Bhoori S, Schiavo M, Mariani L, et al. Predicting survival after liver transplantation in patients with hepatocellular carcinoma beyond the Milan criteria: a retrospective, exploratory analysis. Lancet Oncol 2009;10:35-43.
12. Japan LCSGo. The general rules for the clinical and pathological study of primary liver cancer. Jpn J Surg 1989;19:98-129.
13. Kanai T, Hirohashi S, Upton MP, Noguchi M, Kishi K, Makuuchi M, et al. Pathology of small hepatocellular carcinoma. A proposal for a new gross classification. Cancer 1987;60:810-9.
14. Hui A-M, Takayama T, Sano K, Kubota K, Akahane M, Ohtomo K, et al. Predictive value of gross classification of hepatocellular carcinoma on recurrence and survival after hepatectomy. J Hepatol 2000;33:975-9.
15. Inayoshi J, Ichida T, Sugitani S, Tsuboi Y, Genda T, Honma N, et al. Gross appearance of hepatocellular carcinoma reflects E-cadherin expression and risk of early recurrence after surgical treatment. J Gastroenterol Hepatol 2003;18:673-7.
16. Chen J, Zhao J, Ma R, Lin H, Liang X, Cai X. Prognostic significance of E-cadherin expression in hepatocellular carcinoma: a meta-analysis. PLoS One 2014;9:e103952.
17. Rhee H, Chung T, Yoo JE, Nahm JH, Woo HY, Choi GH, et al. Gross type of hepatocellular carcinoma reflects the tumor hypoxia, fibrosis, and stemness-related marker expression. Hepatol Int 2020;14:239-48.

18. Nart D, Yaman B, Yilmaz F, Zeytunlu M, Karasu Z, Kiliç M. Expression of matrix metalloproteinase-9 in predicting prognosis of hepatocellular carcinoma after liver transplantation. Liver Transpl 2010;16:621-30.
19. Chen R, Cui J, Xu C, Xue T, Guo K, Gao D, et al. The significance of MMP-9 over MMP-2 in HCC invasiveness and recurrence of hepatocellular carcinoma after curative resection. Ann Surg Oncol 2012;19(Suppl 3):S375-84.
20. Adhoute X, Pénaranda G, Raoul JL, Pietri O, Bronowicki JP, Castellani P, et al. Hepatocellular carcinoma macroscopic gross appearance on imaging: predictor of outcome after transarterial chemoembolization in a real-life multicenter French cohort. Eur J Gastroenterol Hepatol 2019;31:1414-23.
21. Hashimoto T, Nakamura H, Hori S, Tomoda K, Nakanishi K, Murakami T, et al. Hepatocellular carcinoma: efficacy of transcatheter oily chemoembolization in relation to macroscopic and microscopic patterns of tumor growth among 100 patients with partial hepatectomy. Cardiovasc Intervent Radiol 1995;18:82-6.
22. Hung YW, Lee IC, Chi CT, Lee RC, Liu CA, Chiu NC, et al. Radiologic Patterns Determine the Outcomes of Initial and Subsequent Transarterial Chemoembolization in Intermediate-Stage Hepatocellular Carcinoma. Liver Cancer 2024;13:29-40.
23. Kudo M, Han KH, Ye SL, Zhou J, Huang YH, Lin SM, et al. A Changing Paradigm for the Treatment of Intermediate-Stage Hepatocellular Carcinoma: Asia-Pacific Primary Liver Cancer Expert Consensus Statements. Liver Cancer 2020;9:245-60.
24. Kudo M, Kawamura Y, Hasegawa K, Tateishi R, Kariyama K, Shiina S, et al. Management of Hepatocellular Carcinoma in Japan: JSH Consensus Statements and Recommendations 2021 Update. Liver Cancer 2021;10:181-223.