

Exacerbation of Autoimmune Hepatitis following Inactivated SARS-CoV-2 Vaccination

Siwanon Nawalerspanya, M.D.^{1,2}, Kontee Wongseeree, M.D.², Pimsiri Sripongpun, M.D.²,
Naichaya Chamroonkul, M.D.², Apichat Kaewdech, M.D.²

¹Department of Internal Medicine, Phaholponpayuhasena Hospital, Kanchanaburi 71000, Thailand.

²Gastroenterology and Hepatology Unit, Department of Internal Medicine, Faculty of Medicine, Prince of Songkla University, Songkhla 90110, Thailand.

Received 28 July 2023 • Revised 28 September 2023 • Accepted 3 October 2023 • Published online 31 January 2024

Abstract:

Autoimmune hepatitis (AIH) is a rare condition that has seldom been reported being reactivated by a coronavirus disease 2019 (COVID-19) vaccination, especially from an inactivated vaccine. This report presents the case of a 64-year-old male with quiescent AIH cirrhosis who exhibited jaundice and constitutional symptoms for three days at two weeks following his second dose of an inactivated vaccine. The patient had complied well with a four-year immunosuppressive medication regimen to treat AIH which maintained normalized liver enzymes. He also abstained from using herbal supplements. At his presentation, his liver chemistry showed acute hepatocellular jaundice, with histology revealing active AIH. Following extensive testing, he was diagnosed with an AIH exacerbation triggered by the COVID-19 vaccine. His symptoms improved following treatment with higher doses of immunosuppressive agents. This report underscores the potential effect of the COVID-19 vaccine on reactivating well-controlled AIH.

Keywords: autoimmune hepatitis (AIH), COVID-19, liver, SARS-CoV-2, vaccination

Contact: Apichat Kaewdech, M.D.
Gastroenterology and Hepatology Unit, Department of Internal Medicine,
Faculty of Medicine, Prince of Songkla University, Hat Yai, Songkhla 90110, Thailand.
E-mail: apichat.ka@psu.ac.th

J Health Sci Med Res 2024;42(4):e20241030
doi: 10.31584/jhsmr.20241030
www.jhsmr.org

© 2024 JHSMR. Hosted by Prince of Songkla University. All rights reserved.
This is an open access article under the CC BY-NC-ND license
(<http://www.jhsmr.org/index.php/jhsmr/about/editorialPolicies#openAccessPolicy>).

Introduction

In December 2019, a novel coronavirus disease emerged (COVID-19), which was named severe acute respiratory syndrome coronavirus 2 (SARS-CoV-2), and quickly disseminated worldwide. As it affected both people's health and overall socioeconomic status there were coordinated efforts to control disease spread, which included various types of COVID-19 vaccines being soon developed and studied in humans¹⁻³. In addition, there were also ongoing studies of the vaccine benefits, safety and side effects. In many clinical trials, the reported side effects were usually mild and localized, such as swelling at the injection site, fever, or myalgia. However, serious side effects, such as seizure, thrombotic thrombocytopenia, and even autoimmunity have been reported in post-marketing data³⁻⁶.

Both de-novo autoimmune hepatitis (AIH) and exacerbation of pre-existing AIH following COVID-19 vaccination have been reported in rising numbers in recent studies, most of which were mRNA and viral vector type vaccines, with scarce data on inactivated vaccines^{5,7-10}. Herein we describe one of the first reported cases of AIH exacerbation after receiving a conventional inactivated whole-virion SARS-CoV-2 vaccine (CoronaVac).

Case report

A 64-year-old Thai male presented with constitutional symptoms and jaundice for 3 days at 2 weeks after receiving a second dose of an inactivated COVID-19 vaccine (CoronaVac), 4 weeks after the first dose.

He had been diagnosed in 2018 with AIH and cirrhosis, which had been well controlled with normalization of liver enzymes and immunoglobulin G (IgG) levels for at least 2 years, following a regimen of low-dose prednisolone and 50 mg/day of azathioprine. However, the azathioprine was discontinued in September 2019 due to tuberculous peritonitis. The patient maintained good adherence to this

regime, including a weekly dose of 15 mg prednisolone. At the presentation of his vaccination problem, he had no abdominal pain, fever, diarrhea, nausea-vomiting, other organ-specific symptoms, or apparent clinical symptoms of COVID-19 disease. He did not use alcohol, over-the-counter drugs, or herbs, and had not travelled recently.

On physical examination, his vital signs were within normal limits; physically he was hypersthenic with marked icteric sclerae and positive signs of chronic liver disease. His abdominal examination was unremarkable, with impalpable liver and spleen, and no ascites. His neurological examination was unremarkable, including a negative flapping tremor test.

His laboratory results showed hemoglobin 15.8 g/dL (13-18 g/dL), white blood cells 4,980/mm³ (4,500-10,000/mm³), and platelets 161,000/mm³ (150,000-450,000/mm³). A coagulogram showed a prothrombin time (PT) 16.3 sec (10.0-12.4 sec), international normalized ratio (INR) 1.50, and partial thromboplastin time (PTT) 31.7 sec (21.2-29.7 sec). A liver function test showed total bilirubin 14.4 mg/dL (0-1.2 mg/dL), direct bilirubin 12.3 (0-0.3 mg/dL), aspartate aminotransferase (AST) 995 U/L (10-50 U/L), alanine aminotransferase (ALT) 969 U/L (10-50 U/L), alkaline phosphatase (ALP) 125 U/L (40-130 U/L), albumin 3.5 g/dL (3.5-5.2 g/dL), and globulin 5.5 g/dL. Blood chemistry showed blood urea nitrogen 8.7 mg/dL (6-20 mg/dL) and creatinine 0.91 mg/dL (0.67-1.17 mg/dL). A nasopharyngeal swab and real-time reverse transcription polymerase chain reaction (RT-PCR) reported COVID-19 undetectable. Serologic testing for anti-nuclear antibodies (ANA) showed a positive homogeneous pattern 1:5120, fine speckled pattern 1:1280, cytoplasmic staining 1:640, anti-smooth muscle antibodies (SMA) negative, anti-mitochondrial antibodies (AMA) negative, and serum IgG level at 3,670 mg% (700-1,600 mg%).

An upper abdominal ultrasound showed a cirrhotic liver, without any space-occupying lesions, and a

non-significant dilated common bile duct from post-cholecystectomy status, with normal spleen size and no ascites.

Other laboratory investigations were conducted for viral serologic evaluation. Tests for hepatotropic viral hepatitis were negative, including hepatitis A (hepatitis A virus IgM), B (hepatitis B surface antigen), C (hepatitis C virus RNA), and E (hepatitis E virus RNA) infections. Molecular diagnosis for non-hepatotropic viral hepatitis was also negative. This included tests for herpes simplex virus types 1 and 2, varicella-zoster virus, Epstein-Barr virus, cytomegalovirus, and human herpes virus types 6 and 7.

Then, a percutaneous liver biopsy was done to obtain a tissue histopathological diagnosis. The pathological report showed severe cholestasis, with focal periportal necrosis and severe parenchymal injury, including portal inflammation composed of lymphoplasmacytic infiltration (Figure 1). These findings were consistent with active AIH.

Overall, his clinical and laboratory findings were a definite diagnosis for active AIH (8 points for the simplified scoring system and 18 points for the International Autoimmune Hepatitis Group (IAIHG) criteria). Based on this diagnosis, he was started on a high dose of dexamethasone, equivalent to prednisolone 1 mg/kg/day for 4 days, during which he gradually improved. He was discharged on day 9 of admission and was given prednisolone 40 mg/day as home medication.

During the follow-up period at the gastroenterology outpatient department, his clinical symptoms continued to improve, with normalizing liver function tests and IgG levels (Figure 2). Then the steroid was gradually tapered to 5 mg/day at 6 months, combined with azathioprine 50 mg. There were no treatment-related adverse events during the follow-up such as infection, new onset diabetes mellitus or drug-induced cytopenia.

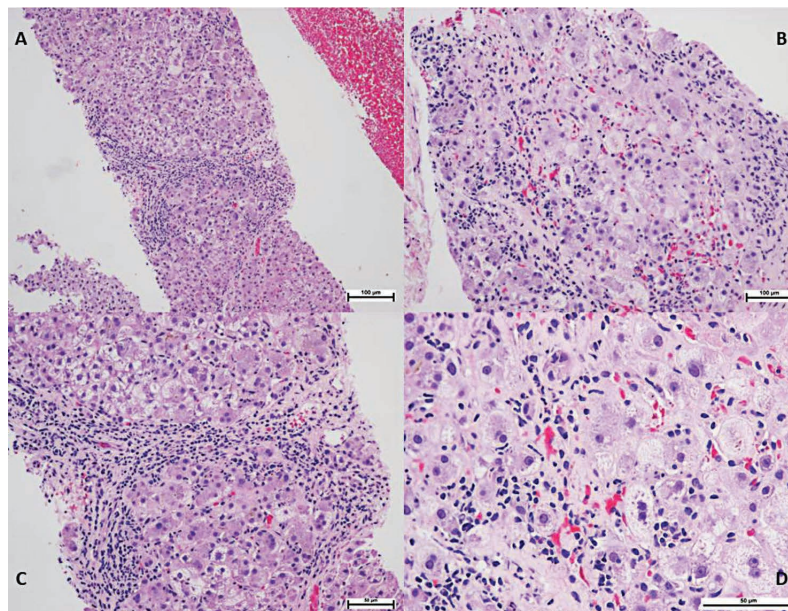
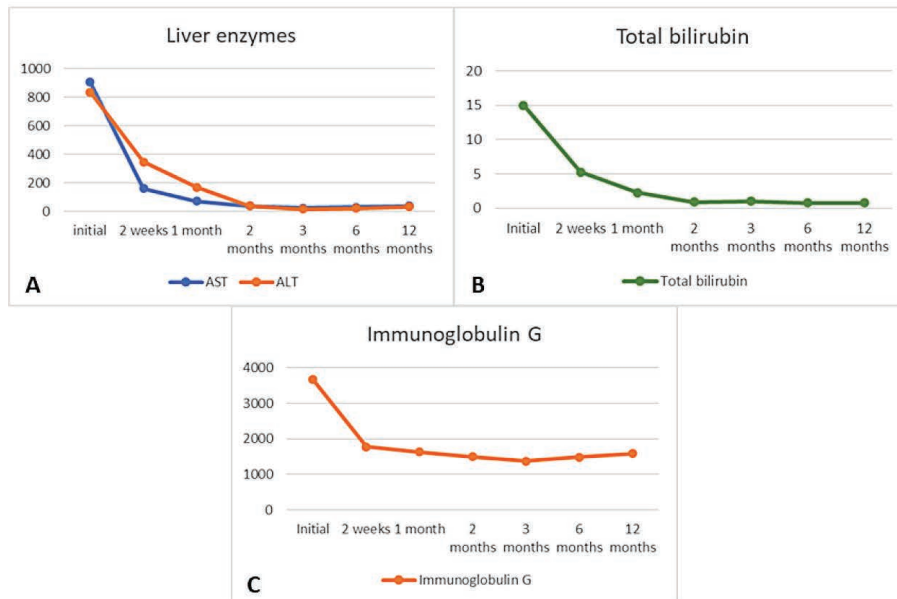


Figure 1 Hematoxylin and Eosin (H&E) stained sections of a core biopsy specimen obtained from the patient's liver. Liver biopsy showing (A) parenchymal injury, with portal inflammation (H&E; 10x). (B and C) Periportal hepatitis and necrosis (H&E; 20x). (D) Lymphocytes and plasma cells infiltrating portal tracts (H&E; 40x).



AST=aspartate aminotransferase, ALT=alanine aminotransferase

Figure 2 The laboratory parameters the first year following initiation of treatment for the re-activation of the AIH following the covid vaccination. (A) Levels of plasma AST, ALT (U/L). (B) Levels of total bilirubin (mg/dL). (C) Levels of total immunoglobulin G (mg%)

Discussion

Herein we present a case of SARS-CoV-2 vaccine-induced AIH exacerbation in a 64-year-old male having previous well-controlled AIH for 2 years. Although vaccination-induced AIH is a rare side effect of vaccination, recently there have been an increasing number of reports of either de-novo or exacerbation of AIH following a COVID-19 vaccination; most of these cases have been associated with mRNA (Pfizer-BioNTech or Moderna) or viral vector (Covishield) type vaccines^{5,7-11}. Our case involved an AIH exacerbation after a second dose of an inactivated whole-virion SARS-CoV-2 vaccine (CoronaVac), an unusual complication for which there are scarce data.

AIH is an immune-mediated chronic inflammatory liver disease. The diagnosis is based on clinical, laboratory, and histological features. The simplified scoring system or

the IAIHG criteria is used for diagnosis. This condition has detectable autoantibodies such as ANA, SMA, anti-liver/kidney microsome type 1 (anti-LKM1), or anti-soluble liver antigen/liver pancreas (anti-SLA/LP), and usually has elevated levels of IgG^{12,13}.

The exact pathogenesis of AIH following vaccination is not well understood. One of the possible proposed mechanisms is molecular mimicry, which is defined as the similarity between a host epitope and an epitope from the vaccine. This allows cross-reactivity activation of the immune process and produces pathogenic autoantibodies, which affect the liver parenchyma¹⁴. Regarding tissue histopathology, currently, no pathognomonic or strongly associated feature has been identified which can differentiate between natural AIH exacerbation and vaccine-induced AIH exacerbation¹⁵.

In this case, a careful workup excluded other possible causes of liver injury such as hepatotoxic drugs/agents and either hepatotropic or non-hepatotropic viral infections. Based on the patient's history, laboratory investigations, liver histopathological diagnosis, and the AIH scoring system, a confident, definite diagnosis of AIH exacerbation could be made. The temporal relationship between his COVID-19 vaccination and the onset of AIH exacerbation, despite over two years of disease control, along with an extensive workup to rule out every other possible cause and observe post-treatment responses, it was concluded that these findings were likely to be a correlation rather than a coincidence.

Conclusion

During a vaccine development period, patients having chronic liver diseases or autoimmune diseases with immunosuppressive agents are usually excluded from the vaccination trials. Hence, there is limited supporting data regarding efficacy and safety for these patients. This report is an instance of a post-marketing report of adverse effects of a COVID-19 vaccine in one patient. Although previous studies have shown that nearly all types of COVID-19 vaccines can trigger AIH, the benefits of vaccines still overwhelm and surpass the risks from side effects. Post-vaccination monitoring should be emphasized, especially in high-risk autoimmunity and autoimmune disease patients, or patients with pre-existing liver diseases. More evidence is required to establish a cause-effect relationship between COVID-19 vaccination and exacerbation of autoimmune hepatitis and help in the guidance and management of adverse events from COVID-19 vaccines, as presently the only management is early recognition and prompt treatment.

Acknowledgement

We extend our gratitude to Ms. Supannarangsri Pongpanich, the study coordinator, for her exceptional

preparation of the laboratory work. We also wish to acknowledge Mr. Andrew Jonathan Tait and Mr. David Leslie Patterson for their proficient editing of the manuscript to ensure the accuracy of the English language.

Funding sources

The authors received no financial support for this article's research, authorship, or publication.

Conflict of interest

All authors have no conflicts of interest to declare.

References

1. Zhao J, Zhao S, Ou J, Zhang J, Lan W, Guan W, et al. Covid-19: coronavirus vaccine development updates. *Front Immunol* 2020;11:602256.
2. Freeman D, Loe BS, Yu LM, Freeman J, Chadwick A, Vaccari C, et al. Effects of different types of written vaccination information on COVID-19 vaccine hesitancy in the UK (OCEANS-III): a single-blind, parallel-group, randomised controlled trial. *Lancet Public Health* 2021;6:e416-27.
3. Teijaro JR, Farber DL. COVID-19 vaccines: modes of immune activation and future challenges. *Nat Rev Immunol* 2021;21:195-7.
4. Dighriri IM, Alhusayni KM, Mobarki AY, Aljerary IS, Alqurashi KA, Aljuaid FA, et al. Pfizer-biontech covid-19 vaccine (bnt162b2) side effects: a systematic review. *Cureus* 2022;14:e23526.
5. Camacho-Domínguez L, Rodríguez Y, Polo F, Restrepo Gutierrez JC, Zapata E, Rojas M, et al. COVID-19 vaccine and autoimmunity. a new case of autoimmune hepatitis and review of the literature. *J Transl Autoimmun* 2022;5:100140.
6. De Michele M, Kahan J, Berto I, Schiavo OG, Iacobucci M, Toni D, et al. Cerebrovascular Complications of COVID-19 and COVID-19 Vaccination. *Circ Res* 2022;130:1187-203.
7. Avci E, Abasiyanik F. Autoimmune hepatitis after SARS-CoV-2 vaccine: New-onset or flare-up? *J Autoimmun* 2021;125:102745.
8. Bril F, Al Diffalha S, Dean M, Fettig DM. Autoimmune hepatitis developing after coronavirus disease 2019 (COVID-19) vaccine: causality or casualty? *J Hepatol.* 2021;75:222-4. -

9. Clayton-Chubb D, Schneider D, Freeman E, Kemp W, Roberts SK. Autoimmune hepatitis developing after the ChAdOx1 nCoV-19 (Oxford-AstraZeneca) vaccine. *J Hepatol* 2021 ;75:1249–50.
10. Garrido I, Lopes S, Simões MS, Liberal R, Lopes J, Carneiro F, et al. Autoimmune hepatitis after COVID-19 vaccine – more than a coincidence. *J Autoimmun* 2021;125:102741.
11. Rela M, Jothimani D, Vij M, Rajakumar A, Rammohan A. Auto-immune hepatitis following COVID vaccination. *J Autoimmun* 2021;123:102688.
12. Domerecka W, Kowalska-Kępczyńska A, Michalak A, Homa-Mlak I, Mlak R, Cichoż-Lach H, et al. Etiopathogenesis and diagnostic strategies in autoimmune hepatitis. *Diagnostics (Basel)* 2021;11:1418.
13. European Association for the Study of the Liver. EASL Clinical Practice Guidelines: Autoimmune hepatitis. *J Hepatol* 2015;63:971–1004.
14. Perumalswami P, Peng L, Odin JA. Vaccination as a triggering event for autoimmune hepatitis. *Semin Liver Dis* 2009;29:331–4.
15. Codoni G, Kirchner T, Engel B, Villamil AM, Efe C, Stättermayer AF, et al. Histological and serological features of acute liver injury after SARS-CoV-2 vaccination. *JHEP Rep* 2023;5:100605.