

A Comparison of Intra–Observer and Inter–Observer Reliability of Plain Radiographs, Standard Computed Tomography Scans and Mobile Computed Tomography Scans in the Assessment of Distal Radius Fractures: A Cadaveric Study

Sitthiphong Suwannaphisit, M.D., Saowapark Yoykaew, M.Sc., Chitchaya Suwanraksa, M.Sc.,
Varah Yuenyongviwat, M.D., Porames Suwanno, M.D., Sittichoke Anuntaseree, M.D.

Department of Orthopedics, Faculty of Medicine, Prince of Songkla University, Hat Yai, Songkhla 90110, Thailand.

Received 12 June 2019 • Revised 4 November 2019 • Accepted 23 November 2019 • Published online 26 December 2019

Abstract:

Objective: Diagnosis of a distal end radius fracture relies on various imaging studies. However, the relative usefulness of these studies is still a matter of some controversy. The aim of this study was to compare the intra–observer and inter–observer reliability of plain radiographs, standard computed tomography (CT) scans and mobile CT scans in the assessment of distal radius fractures as categorized by the Fernandez classification method. The secondary objective was to compare the dosages of radiation between the different imaging modalities.

Material and Methods: Sixteen fresh cadaveric wrist bones were used in this experimental study. The desired fractures were created in the bones to mimic Fernandez types I–V fractures and plain radiographs were taken in 4 views. Standard CT and mobile CT scans were also taken with the fractured bones in the same four positions. Inter–observer reliability was assessed using Kappa statistics to determine the diagnostic consistency among the nine observers. Inter–observer agreement was assessed based on the Fernandez classification system diagnoses.

Results: Overall, the inter–observer agreement was substantial for the Fernandez classifications (Kappa range 0.636–0.727) in all types of imaging. For intra–observer agreement, the analysis found higher agreement for both standard CT scans and mobile CT scans. The standard CT images imparted a higher average dose of radiation than both the mobile CT scans and the plain radiographs.

Contact: Sitthiphong Suwannaphisit, M.D.
Department of Orthopedics, Faculty of Medicine,
Prince of Songkla University, Hat Yai, Songkhla 90110, Thailand.
E-mail: aunsittipong@gmail.com

J Health Sci Med Res 2020;38(1):53–59
doi: 10.31584/jhsmr.202078
www.jhsmr.org

© 2020 JHSMR. Hosting by Prince of Songkla University. All rights reserved.
This is an open access article under the CC BY–NC–ND license
(<http://www.jhsmr.org/index.php/jhsmr/about/editorialPolicies#openAccessPolicy>).

Conclusion: The mobile CT scan can provide an alternative imaging method for precise diagnosis of distal end radius fractures, with the additional benefits of mobility and lower radiation exposure.

Keywords: computed tomography, distal radius fractures, Fernandez classification, imaging

Introduction

Diagnosis of distal end radius fractures does not need a computed tomography (CT) scan. CT scans are usually obtained for better assessment of the fracture pattern for complex intra-articular fractures. There are various types of imagings used for this purpose, most commonly plain radiographs, standard CT scans, and mobile CT scans. The main benefit of a plain radiograph is that it is convenient. However, some types of fractures can be missed when using this investigation, and the standard CT scan has become an integral part of modern treatment for most fractures, including complex distal radius fractures, because it provides high quality images, allowing a more precise diagnosis and thus optimal treatment.¹ There are some disadvantages to a standard CT scan, however, notably that it is costly, and also exposes the patient to a higher dose of radiation than the traditional X-ray. In recent years, the mobile CT has become increasingly popular in dental and maxillofacial applications due to its low cost, small machine size, and 3D data information.^{2,3} Due to its mobility, it can be used to provide better and faster images for patients at various clinical sites, for example in the operating room for pre- and post-operation imaging without moving the patient out of the operating room, which reduces the risk associated with patient transport to the radiology department, especially in emergency and critical situations.

To date there have been no studies comparing the reliability of the mobile CT scan versus the standard CT scan in the assessment of distal radius fractures. The aim of this study was to compare the intra-observer and

inter-observer reliability of plain radiographs, standard CT scans and mobile CT scans in the assessment of distal radius fractures as categorized by the Fernandez classification method. The secondary objective was to compare the dosages of radiation between the different imaging modalities.

Material and Methods

Approval for the study was obtained from the Institutional Review Board of the Human Research Ethics Committee, Faculty of Medicine, Prince of Songkla University (REC 60-397-11-1). Sixteen fresh cadaveric wrist bones from legally donated cadavers were obtained for the study. The desired fractures were created in the bones to mimic the Fernandez classifications types I-V. The fracture patterns were created in 5 groups: (a) extra-articular distal end radius fractures (4 specimens), (b) shearing type distal end radius fractures (4 specimens), (c) axial compression type distal end radius fractures (4 specimens), (d) avulsion type distal end of radius fractures (2 specimens), and (e) combined distal end of radius fractures (2 specimens).

Three imaging studies were performed on each fractured bone, a plain radiograph (digital radiograph, Samsung, series/GC85A), a Multi-detector computed tomography machine (MDCT) (Toshiba Aquilion Prime with 80 row detector), and a mobile CT scanner (Mobii Scan version 1.1 and MobiiScan Software Version 2.0). The plain radiographs were taken in 4 positions, postero-anterior (PA) and lateral views, semi-pronated 45° and semi-supinated 45°. Standard CT and mobile CT scans

were also taken with the fractured bones in the same four positions.

The standard CT scanner was operated in the helical scanning mode with kilo-voltage peak (kVp) of 120 kVp, tube current (milliamperere; mA) of 80 mA, rotation time of 0.5 seconds, and slice width collimation of 0.5×80.0 millimeter (mm). The mobile CT scans were acquired using a kVp of 90 kVp, tube current (mA) of 6 mA, slice thickness of 0.3 mm/pixel, and diameter and height of voxel of 12 centimeter each. The plain PA radiographs in the semi-pronated oblique and semi-supinated oblique positions used a kVp of 50 kVp and mA-seconds (mAs) of 3.2 mAs while the lateral images were taken at 54 kVp and 3.2 mAs.

For estimates of the effective dose (E), dose-length product (DLP) conversion factors for standard CT and mobile CT were used, while the plain radiographs used dose-area-product (DAP) and conversion factors to determine the E.

All radiographs and standard CT and mobile CT scans were rendered unidentifiable and assigned random numbers by an independent person. The same person was responsible for the collection of the responses from the assessors and for collating the radiographs, CT scans and mobile CT images at the end of the classification process. The evaluations of the radiographs, standard CT scans and mobile CT images were performed in different sessions in order to reduce outcome bias. The assessors were divided into 3 groups. The 1st group comprised 3 Orthopedic senior residents, the 2nd group had 3 general orthopedic surgeons with less than 5 years of experience in wrist surgery, and the last group had three orthopedic hand surgeons. All assessors were asked to individually classify the fractures according to the Fernandez classification system, and were provided with a written and illustrated description of the system to facilitate the evaluation process and increase the accuracy of their

evaluation. The evaluations were conducted in three different periods. The 1st period was used for interpretation of the mobile CT scans, 1 week later the plain radiographs were evaluated, and again 1 week later the standard CT scans were evaluated. The benchmark for all assessments was the actual record of the created fractures.

Inter-observer reliability analysis was measured using Kappa statistics to determine consistency among the observers. Inter-observer agreement was assessed based on the Fernandez classification system diagnoses.

Kappa values can range from -1.0 to 1.0, with -1.0 indicating perfect disagreement below chance, 0.0 indicating agreement equal to chance and 1.0 indicating perfect agreement above chance. A Kappa of 0.700 or above indicates adequate inter-observer agreement.⁴ The range of Kappa values is divided into 6 categories, Kappa <0.000 (poor agreement), Kappa 0.000–0.200 (slight agreement), Kappa 0.210–0.400 (fair agreement), Kappa 0.410–0.600 (moderate agreement), Kappa 0.610–0.800 (substantial agreement), and Kappa 0.810–1.000 (perfect agreement).

Results

The diagnostic performances of each test following the Fernandez classification are presented in Figures 1, 2, and 3. The level of intra-observer agreement among the plain radiographs, CT scans and mobile CT scans using the Fernandez classification system is presented in Table 1.

Overall, the inter-observer agreement was substantial for the Fernandez classifications (Kappa range 0.636–0.727) for the X-rays, standard CT scans and mobile CT scans. The best values for the Fernandez classification system were found for the standard CT scans (Kappa=0.727), while the poorest agreements were found for the mobile CT scans (Kappa=0.636).

Table 1 Intra-observer agreement between each imaging format compared against the actual fracture according to the Fernandez classification of distal radius fractures

Observer	Plain radiography		Stand CT scan		Mobile CT scan	
	Percent of intraobserver agreement (%)	Kappa	Percent of intraobserver agreement (%)	Kappa	Percent of intraobserver agreement (%)	Kappa
1	81.3	0.754	81.3	0.755	93.8	0.920
2	75.0	0.675	93.8	0.918	87.5	0.838
3	81.3	0.754	87.5	0.837	87.5	0.838
4	75.0	0.675	81.3	0.755	93.8	0.919
5	56.3	0.404	68.8	0.590	56.2	0.434
6	50.0	0.323	68.8	0.574	68.8	0.568
7	68.8	0.598	81.3	0.755	75.0	0.672
8	75.0	0.680	68.8	0.604	93.8	0.918
9	68.8	0.588	75.0	0.667	75.0	0.667
Means	70.1	0.600	78.5	0.717	81.3	0.752

CT=computed tomography

Observers number 1-3 were hand surgeons, 4-6 senior residents, and 7-9 orthopedic surgeons with 5 or less years experience

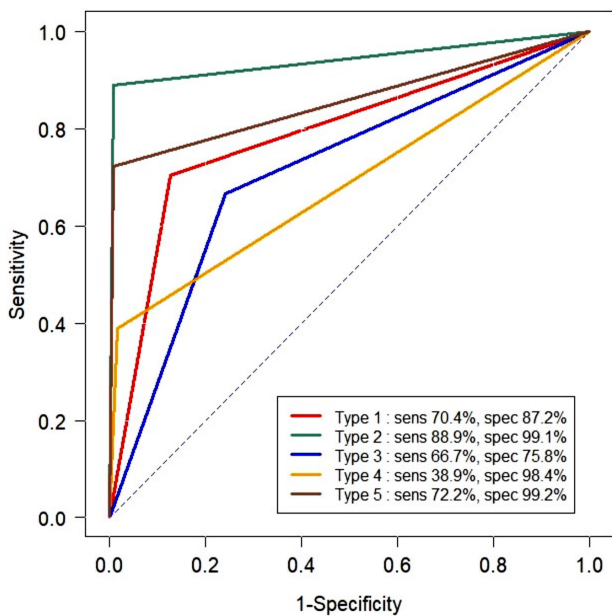


Figure 1 Diagnostic assessments of the observers using plain radiography for the 5 types of Fernandez classification distal radius fractures

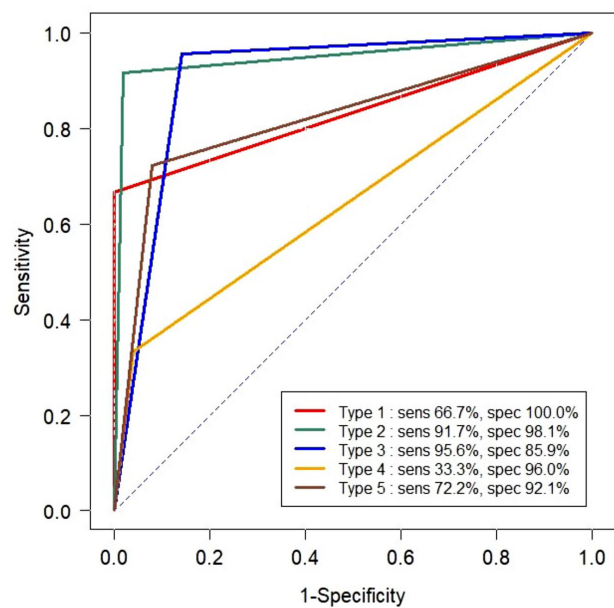


Figure 2 Diagnostic assessments of the observers using standard computer tomography for the 5 types of Fernandez classification distal radius fractures

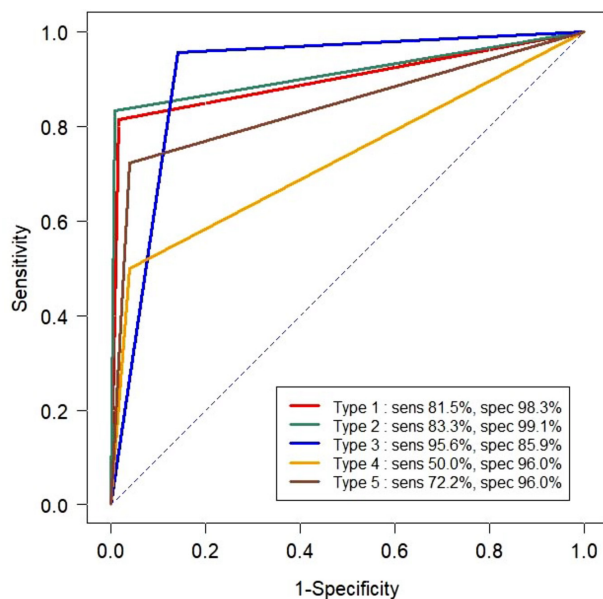


Figure 3 Diagnostic assessments of the observers using mobile computer tomography for the 5 types of Fernandez classification distal radius fractures

Looking closer at the subgroups, for intra-observer agreement, the study found that the senior hand surgeons group (observers 1–3) had substantial agreement (Kappa range 0.675–0.754) when using plain radiography, while interpretation of standard CT scans showed almost perfect agreement with Kappa scores ranging from 0.755–0.918, and mobile CT scans had even higher agreement scores of 0.838–0.920. Regarding the senior orthopedic residents group (observers 4–6), they overall showed fair to substantial agreement (Kappa range 0.323–0.675) for plain radiographs, and higher agreement for both standard CT scans (0.574–0.755) and mobile CT scans (0.434–0.919). For the general orthopedic group (observers number 7–9), the analysis found moderate to substantial agreement for plain radiographs (Kappa range 0.588–0.680) and again increased Kappa scores for standard CT scans (0.604–0.755) and mobile CT scans (0.667–0.918).

Comparing average radiation doses, the standard CT images imparted a higher average dose than both

the mobile CT and the plain radiograph. The difference between the standard CT and mobile CT was significant with a p -value < 0.001 . The mean CT dose–index volumes ($CTDI_{vol}$) of the standard CT and mobile CT were 5.20 and 2.35 milligrays (mGy) and the DLPs were 85.360 ± 0.720 (83.000 – 86.200) and 28.16 mGy.cm, respectively. For the plain radiographs, the mean $DAP \pm S.D.$ and ranges of PA, LAT, semi-pronated oblique and semi-supinated oblique were 0.060 ± 0.002 (0.050 – 0.060), 0.090 ± 0.010 (0.060 – 0.110), 0.060 ± 0.004 (0.050 – 0.070), and 0.060 ± 0.005 (0.040 – 0.070) dGy.cm², respectively.

In terms of image quality, we found that the mean signal to noise ratios (SNR) of standard CT and mobile CT scans were 1.600 ± 0.370 , 3.110 ± 1.010 , and of the plain radiographs in the PA, lateral and semi-pronated oblique and semi-supinated oblique positions were 12.370 ± 1.780 , 14.390 ± 3.420 , 11.010 ± 3.620 and 11.570 ± 3.520 , respectively.

Discussion

The purpose of this study was to compare the accuracy of X-rays, standard CT scans and mobile CT scans when diagnosed by differently experienced orthopedists according to the Fernandez classification system which is commonly used to assess distal end of radius fractures. The Fernandez classification was chosen because it is relatively easy to use and is commonly used in practice.

Many studies^{5–8} have compared the various classification systems used to assess distal radius fractures and assessed the validity and reliability among them. Our study focused on the accuracy of diagnosis of each type of Fernandez classification fracture, which is based on mechanism of injury⁹, according to the type of imaging study used. It is notable that the lowest sensitivity in all images was found in the Fernandez type IV fractures. We believe this is because the Fernandez type IV fractures are the least common fractures, and many

doctors are less concerned about this type of fracture and tend to assign them a type III classification.

The use of CT scans can help reduce the frequency of this misdiagnosis, particularly with small degree fractures or with a fracture line extending to the sigmoid notch, which are most commonly misdiagnosed by more inexperienced surgeons. Harness et al.⁹ suggested that three-dimensional reconstruction (3D/CT) should be performed if possible, as this technique improves the identification of the fracture fragments and thus influences treatment decisions and patient outcomes.¹⁰ Our results are similar to other studies regarding the addition of 3D/CT and its ability to increase intra-observer reliability.^{5,11} However, our results are in contrast to a study by Arealis et al.⁴, which found that the Fernandez classification was less affected by an additional CT scan. This might be related to the experience of the doctors, as in our study the senior doctors had more accurate readings the first time with the plain radiography and the MDCT scans may be helpful only for diagnosis of intra-articular distal end radius fractures. For the more common extra-articular fractures, the MDCT, mobile CT and plain radiographs are equally reliable.

The results of our study suggest that the use of a mobile CT scanner can provide similar diagnostic accuracy as a standard CT scanner. However, CT scans do have limitations that must be considered, in that they expose the patient to a higher dose of radiation and are more expensive than the traditional X-ray.

The major benefit of the mobile CT scan is its mobility, as it gives the physician better and faster access to CT images for patients at various clinical sites, for example, in the operating room both pre- and post-operatively without needing to move a patient out of the operating room, reducing the risk associated with transporting the patient to the radiology department, especially in emergency and critical situations.

The radiation doses for standard CT and mobile CT scanners are reported as the $CTDI_{vol}$ and DLP, and measured in mGy. For each modality, the $CTDI_{vol}$ is presented the same in all studies because the parameters are constant. The DLP of the standard CT shows slight differences in reported studies due to scan length. In contrast, the DLPs in mobile CTs are the same because of its constant field of view (FOV). The $CTDI_{vol}$ and DLP of the standard CT give higher radiation doses than the mobile CT due to higher voltage (kVp) tube current (mA).

The radiation doses for plain radiography are reported as DAP. In the current study, the positions used for the plain radiographs were PA, lateral, semi-pronated oblique and semi-supinated oblique. The DAPs of the lateral position had higher radiation doses because of the greater thickness than in the other positions. The image quality was reported in terms of signal to noise ratio (SNR). The SNRs for standard and mobile CTs were calculated by means of the CT number in the region of interest divided by S.D., while the SNRs of the plain radiographs were calculated using pixel values in units of US divided by S.D. The plain radiographs had the highest SNRs, while the standard CTs had slightly lower SNRs than the mobile CTs. All imaging modalities had good SNR values ($SNR > 1$). However, the mobile CT had some limitations such as FOV.

In our study, the radiation doses to patients from the mobile CT were lower than from the standard CTs. However, the medical staff received higher doses of scatter radiation from the mobile CTs than from the standard CTs. Thus, the medical staffs, operated a Mobile CT should use radiation shielding material such as a lead apron and thyroid shield to minimize their exposure to the scatter radiation.

The main limitation of this study was that it was a cadaveric study, and thus the findings may not apply to

all clinical settings. Further studies in real clinical settings are needed.

Conclusion

The mobile CT scan can provide an alternative imaging method for precise diagnosis of distal end of radius fractures, with the additional benefits of mobility and lower radiation exposure.

Acknowledgements

We would like to thank all of the staff from the Epidemiology Unit, Faculty of Medicine, Prince of Songkla University for their assistance in designing this study. We would also like to give a special thanks you to Asst. Prof. Pramot Tanutit of the Radiology Department for setting the standard protocol used during imaging studies.

Conflicts of interest

All authors declare no potential conflicts of interest relevant to this study.

References

1. Kleinlugtenbelt YV, Groen SR, Ham SJ, Kloen P, Haverlag R, Simons MP, et al. Classification systems for distal radius fractures. *Acta Orthop* 2017;88:681–7.
2. De Vos W, Casselman J, Swennen GRJ. Cone-beam computerized tomography (CBCT) imaging of the oral and maxillofacial region: a systematic review of the literature. *Int J Oral Maxillofac Surg* 2009;38:609–25.
3. Ludlow JB, Ivanovic M. Comparative dosimetry of dental CBCT devices and 64-slice CT for oral and maxillofacial radiology. *Oral Surg Oral Med Oral Pathol Oral Radiol Endodontology* 2008;106:106–14.
4. Arealis G, Galanopoulos I, Nikolaou VS, Lacon A, Ashwood N, Kitsis C. Does the CT improve inter- and intra-observer agreement for the AO, Fernandez and Universal classification systems for distal radius fractures? *Injury* 2014;45:1579–84.
5. Kleinlugtenbelt YV, Groen SR, Ham SJ, Kloen P, Haverlag R, Simons MP, et al. Classification systems for distal radius fractures: does the reliability improve using additional computed tomography? *Acta Orthop* 2017;88:681–7.
6. Shehovych A, Salar O, Meyer C, Ford D. Adult distal radius fractures classification systems: essential clinical knowledge or abstract memory testing? *Ann R Coll Surg Engl* 2016;98:525–31.
7. Mulders MAM, Rikli D, Goslings JC, Schep NWL. Classification and treatment of distal radius fractures: a survey among orthopaedic trauma surgeons and residents. *Eur J Trauma Emerg Surg* 2017;43:239–48.
8. Naqvi SGA, Reynolds T, Kitsis C. Interobserver reliability and intraobserver reproducibility of the Fernandez Classification for Distal Radius Fractures. *J Hand Surg Eur Vol* 2009;34:483–5.
9. Harness NG, Ring D, Zurakowski D, Harris GJ, Jupiter JB. The influence of three-dimensional computed tomography reconstructions on the characterization and treatment of distal radial fractures. *J Bone Joint Surg Am* 2006;88:1315–23.
10. Andersen DJ, Blair WF, Steyers CM, Adams BD, el-Khoury GY, Brandser EA. Classification of distal radius fractures: an analysis of interobserver reliability and intraobserver reproducibility. *J Hand Surg* 1996;21:574–82.
11. Ferrero A, Garavaglia G, Gehri R, Maenza F, Petri GJ, Fusetti C. Analysis of the inter- and intra-observer agreement in radiographic evaluation of wrist fractures using the multimedia messaging service. *Hand* 2011;6:384–9.