

Giant Brain Abscess in A Pediatric Patient with Congenital Heart Disease: A Case Report

Aji Setia Utama, M.D., Muhammad Arifin Parenrengi, M.D., Ph.D.

Department of Neurosurgery, Faculty of Medicine Universitas Airlangga – Dr. Soetomo General Academic Hospital, Surabaya 60131, Indonesia.

Received 5 January 2022 • Revised 18 February 2022 • Accepted 21 February 2022 • Published online 23 March 2022

Abstract:

Cerebral abscesses, or brain abscesses, are a severe condition, can be fatal, and have a high mortality and morbidity rate; especially in children with congenital heart disease. Herein, we report on a 5-year old girl, who developed a giant brain abscess with congenital heart disease; however, regrettably, the patient died 24 hours after her operation. Brain abscesses are still a major consequence of cyanotic congenital heart disease. The development of radiological imaging; especially, computed tomography scans, and continuous updates on antibiotic therapy and minor invasive surgery have decreased the mortality rate; however, it still remains quite high. Brain abscesses in congenital heart disease have many pitfalls, and require a multidisciplinary approach as well as careful preoperative planning to achieve the desired outcome.

Keywords: cause of death, cerebral abscess, child health, congenital heart disease, pediatric

Contact: Muhammad Arifin Parenrengi, M.D., Ph.D.
Department of Neurosurgery, Faculty of Medicine, Universitas Airlangga – Dr. Soetomo
General Academic Hospital, Surabaya 60131, Indonesia.
E-mail: muhammad.arifin@fk.unair.ac.id

J Health Sci Med Res 2022;40(6):695–699
doi: 10.31584/jhsmr.2022872
www.jhsmr.org

© 2022 JHSMR. Hosting by Prince of Songkla University. All rights reserved.
This is an open access article under the CC BY–NC–ND license
(<http://www.jhsmr.org/index.php/jhsmr/about/editorialPolicies#openAccessPolicy>).

Introduction

Brain abscesses are a centralized infection of the brain's nervous system; including the parenchyma. Although, in adults, and more less so in pediatric patients, this illness is rare the risk is higher in a particular patient groups.¹ Additionally, it is a potentially deadly complication in patients with cyanotic congenital heart disease (CHD), as 5.0–18.0% of this group may develop a cardiogenic brain abscess.² One of the most common predispositions to a brain abscess is cyanotic congenital heart disease, and *Streptococcus* spp. is the most common pathogen. Centers for Disease Control and Prevention have stated that congenital anomalies are one of the most common causes, with CHDs in the United States affecting over 1.0% or around 40,000 births annually.³ Recently, brain abscess mortality has been reduced via new diagnostic, neurosurgical techniques and antibiotics; especially, the widespread use of computed tomography (CT) scanning, which makes for early diagnosis, an accurate characterization, and a quick assessment of brain abscess

possibilities.⁴ In this case, antibiotics and surgical evacuation of the abscess becomes the standard therapy;⁵ however, in cases of CHD, management is more complex and challenging.⁶ In this article, we discuss our experience in managing a cerebral abscess in a congenital heart disease patient.

Case report

A 5-year-old female presented to our emergency room, after being screened for the Corona Virus Disease 2019 (COVID-19), with history of decreased consciousness following a seizure one day before hospital admission. The seizures were generalized as tonic-clonic, repeating five times each, with a duration of 1 minute per seizure. After this, the patient experienced dyspnea, and her whole body became cyanotic. From the time she was a newborn, the patient had had history of a major ventricular septal defect, patent ductus arteriosus, and pulmonary atresia. Two months before admission, the patient had gradual weakness

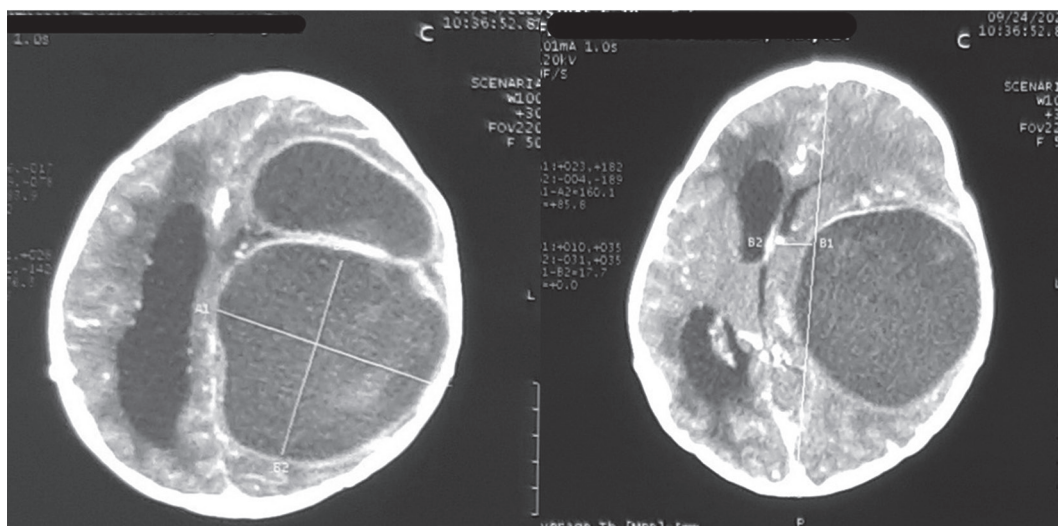


Figure 1 A computed tomography scan of the patient's head showed a ring-shaped hypodense cystic lesion in the left frontotemporoparietal region, resulting in a significant midline shift, with marked ventricular dilatation surrounded by periventricular edema.

and convulsions in all four extremities, with pronounced weakness on the right side. The patient was later diagnosed with a brain abscess, but did not continue therapy at the referring hospital due to poor compliance and restrictions during the COVID-19 pandemic. The patient did not receive any course of antibiotics before admission.

The patient then underwent a contrast-enhanced CT scan of the head that revealed multiple cystic lesions with ring enhancement in the left frontotemporoparietal region. The right lateral, third and fourth ventricles were also dilated with periventricular edema (Figure 1). We decided to perform a small craniotomy to evacuate the open abscess, and to install intracapsular drainage. The patient received pre-operative antibiotics of Cefazoline 1 gr. A postoperative CT scan of the head showed a reduction in the abscess size between the inserted intracapsular canals in the correct position (Figure 2).

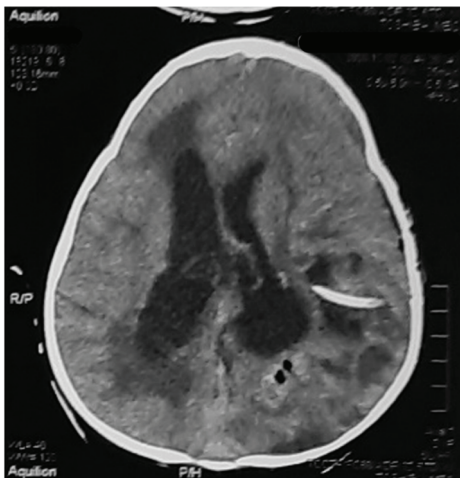

Figure 2 The head's postoperative computed tomography scan showed a massive reduction in abscess size, with intracapsular drainage inserted into the abscess capsule. The midline shift is no longer visible, and the left lateral ventricle was released from the pressure.

The patient was stable in the first few hours after surgery, but then deteriorates rapidly after 24 hours. Postoperative laboratory studies showed an increase in Prothrombin Time (PT) (21.3 seconds) and elevated hemoglobin (21 g/dl). The patient died within 24 hours after surgery: post-mortem culture was not obtained. The possibility of this patient dying was intriguing and required further discussion.

Discussion

CHDs may lead to a brain abscess, due to a right-to-left shunt bypass; in which the blood contains bacteria, as it was not filtered through pulmonary circulation. This leads to direct entry of bacteria to the brains circulation. Patients with CHD usually also have polycythaemia, which can cause a focal area of ischemia, which is susceptible to infection. This mechanism may lead to the development of a brain abscess.⁷

Cases of brain abscesses have long been in the spotlight in pediatric patients with congenital heart disease.⁸ Although, the incidence and mortality rates have decreased significantly compared to the last few decades, due to the development of diagnostic and therapeutic modalities, the mortality rate is still high; approximately 10.0%.² The outcome of a brain abscess in congenital heart disease varies, as the parameters of the abscess depend on the disease and its fundamental characteristics: number, size and location, the kind of abscess organism as well as the intraventricular rupture of brain abscesses (IVROBA). A case study at Sardjito Hospital, Yogyakarta, Indonesia revealed that low peripheral saturation of oxygen as being a significant risk factor for the development of brain abscesses in children with CHD. The incidence of brain abscess may increase by 8.0%, due to a 1.0% reduction in peripheral oxygen saturation.⁹ Factors that may affect the patient's outcome include: history of seizure, cyanosis, type of heart

cyanotic disease, a younger age, an immunocompromised condition, and pre-treatment neurological status. The presence of cyanotic cardiac illness and a severe degree of congenital heart disease contributes considerably to a poor result.

It is a challenge to treat brain abscesses. For both the neurosurgeons and internists, urgent decompression is a preferable option for patients who have severe mass effect and progressive neurological deficit.¹⁰ The selection of the surgical technique has long been a subject of dispute.¹¹ The major option for cardiogenic brain abscess management is the aspiration or excision of the abscess, followed by parenteral antibiotic therapy; as in other cerebral abscesses with a mass impact. Craniotomy is rarely used as a first-line treatment in the period before CT scanning.¹² However, today repeated aspiration, as required or with drainage; in these patients has primarily replaced attempts at complete excision. Aspiration had better results and effects, since it requires a smaller site for aspiration.¹⁰

Arlotti et al., explained that the management of brain abscess can include medical only, or both medical and surgical. Medical treatment might be attempted in patients without severe neurological impairment, for a small abscess, and if they are contraindicated to surgery. In our case, surgery was the best option for our patient. There are two major neurosurgical options for a brain abscess, these being: aspiration and excision with craniotomy. We choose an evacuation of the abscess with craniotomy and insertion of an intracapsular drainage; as it might have minimized risk of recurrence.^{1,13}

Complications of giant brain abscesses widely vary; however, IVROBA is strongly predisposed to poor outcomes in patients with cyanotic heart disease. Mortality rates have been observed as being between 39.0% and 80.0% following IVROBA.¹⁴ The key to reducing the likelihood of a poor outcome is the prevention and management of

IVROBA. The patients outcome is improved greatly by early discovery, and active management in the form of drainage/excision, followed by intrathecal and intravenous antibiotic therapy (depending on sensitivity).¹⁵ Abscesses should be managed by less invasive aspiration methods; such as, guided by computed tomography.¹⁰

However, the rate of mortality in patients with a cardiogenic brain abscess is higher, because of cardiopulmonary risks and numerous coagulation problems for individuals with brain abscess in addition to congenital cyanotic cardiopulmonary disease. This predisposing condition increases the risk of both anaesthesia and surgery.¹⁴ Significantly, higher mortality rate have also been reported in patients with congenital heart disease during aspiration of brain abscesses, which is associated with multiple cyanotic spells and more significant midline shift and cerebral edema. As found in our study, our patient also had an increase in PT, which was most likely due to coagulation disorders because of her congenital heart disease. The sudden deterioration in this patient's condition could also be due to the greater cardiopulmonary risk in these patients; as previously described. The cause of death in this patient cannot be determined for this patient as post-mortem analysis was not conducted.

Conclusion

Despite decades of research, brain abscesses are still a deadly complication of congenital heart disease. The development of radiological imaging; especially CT scans, and continuous updates on antibiotic therapy and minimal invasive surgery have decreased the mortality rate; however, it is still high. Brain abscesses in congenital heart disease patients have many pitfalls and require a multidisciplinary approach along with careful preoperative planning to achieve the desired outcome.

Conflict interest

The authors have declared that no competing interests exist.

References

1. Mameli C, Genoni T, Madia C, Doneda C, Penagini F, Zuccotti G. Brain abscess in pediatric age: a review. *Childs Nerv Syst* 2019;35:1117–28.
2. Mehnaz A, Syed AU, Saleem AS, Khalid CN. Clinical features and outcome of cerebral abscess in congenital heart disease. *JAMC* 2006;18:21–4.
3. Centers for Disease Control and Prevention. Data and statistics on congenital heart defects. Atlanta: Congenital Heart Defects; 2020.
4. Takeshita M, Kagawa M, Yato S, Izawa M, Onda H, Takakura K, et al. Current treatment of brain abscess in patients with congenital cyanotic heart disease. *Neurosurgery* 1997;41:1270–9.
5. Moorthy RK, Rajshekhar V. Management of brain abscess: an overview. *Neurosurg Focus* 2008;24:E3.
6. Parra MM, Hernandez M, Garza EA de, Reyes DP. Brain abscess in pediatric patients with congenital heart disease: a case report and review of the literature. *J Cardiol Curr Res* 2018;11. doi: 10.15406/jccr.2018.11.00370.
7. Lumbiganon P, Chaikitpinyo A. Antibiotics for brain abscesses in people with cyanotic congenital heart disease. *Cochrane Database Syst Rev* 2013;CD004469.
8. Matson D, Salam M. Brain abscess in congenital heart disease. *Pediatrics* 1961;27:772–89.
9. Firdausy NQ, Murni IK, Triono A, Noormanto N, Nugroho S. Low peripheral oxygen saturation as a risk factor for brain abscess in children with cyanotic congenital heart disease. *Paediatr Indones* 2018;58:252–6.
10. Muzumdar D, Jhawar S, Goel A. Brain abscess: an overview. *Int J Surg* 2011;9:136–44.
11. Sharma BS, Gupta SK, Khosla VK. Current concepts in the management of pyogenic brain abscess. *Neurology India* 2000;48:105–11.
12. Tseng JH, Tseng MY. Brain abscess in 142 patients: factors influencing outcome and mortality. *Surg Neurol* 2006;65:557–62.
13. Arlotti M, Grossi P, Pea F, Tomei G, Vullo V, De Rosa FG, et al. Consensus document on controversial issues for the treatment of infections of the central nervous system: bacterial brain abscesses. *Int J Infect Dis* 2010;14:S79–92.
14. Takeshita M, Kawamata T, Izawa M, Hori T. Prodromal signs and clinical factors influencing outcome in patients with intraventricular rupture of purulent brain abscess. *Neurosurg* 2001;48:310–7.
15. Savardekar A, Krishna R, Arivazhagan A. Spontaneous intraventricular rupture of pyogenic brain abscess: a short series of three cases and review of literature. *Surg Neurol Int* 2016;7: 947.