

Triplicate Ureter with Complicated Ureteral Cyst in an Ectopic Malrotated Kidney: A Rare Association

Varun Nimje, M.B.B.S., M.D., Shubham Bodhankar, M.B.B.S., M.D.,
Tushar Yadav, M.B.B.S., M.D.

Department of Radiodiagnosis and Imaging, N.K.P. Salve Institute of Medical Sciences and Lata Mangeshkar Hospital,
Nagpur, Maharashtra, India 440019.

Received 10 August 2022 • Revised 16 August 2022 • Accepted 18 September 2022 • Published online 11 November 2022

Abstract:

One of the rarest anomalies of the renal collecting system is ureteral triplication along with the presence of a complex ureteral cyst. We describe an unusual case of a 37-year-old man who presented with fever and abdominal pain. Computed tomography urography (CTU) revealed triplication of the ureter in association with renal ectopia and a ureteral cyst which was complicated by calculi formation. Following treatment with antibiotics, the patient was managed by open ureterolithotomy with resection of the ureteral cyst and tailoring of the ureter.

Keywords: congenital renal anomaly, ectopic kidney, malrotated kidney, trifid ureter, ureteral cyst

Introduction

The most prevalent congenital anomalies are those involving the urinary tract. Triplication is a rarer occurrence, while duplication of the upper urinary tract is commonly encountered¹. This condition is frequently accompanied with other urinary tract abnormalities. A review of the literature revealed that just around one hundred instances of ureteral triplication had been documented globally².

Urinary tract infections, incontinence, or discomfort may be caused by a triplicate ureter; however, this abnormality is typically asymptomatic. The most frequent abnormality coexisting with ureteral triplication is ureteral duplication in the contralateral collecting system, followed by ureteral ectopia and renal dysplasia³. Various treatment options of this abnormality vary from conservative management to reconstructive surgery⁴.

Contact: Varun Nimje, M.B.B.S., M.D.
Department of Radiodiagnosis and Imaging, NKP Salve Institute of Medical Sciences and
Lata Mangeshkar Hospital, Nagpur, Maharashtra, India 440019.
E-mail: varunnimje12@gmail.com

J Health Sci Med Res 2023;41(3):e2022907
doi: 10.31584/jhsmr.2022907
www.jhsmr.org

© 2022 JHSMR. Hosted by Prince of Songkla University. All rights reserved.
This is an open access article under the CC BY-NC-ND license
(<http://www.jhsmr.org/index.php/jhsmr/about/editorialPolicies#openAccessPolicy>).

We report a rare case of renal ectopia with ureteral triplication which drained into a ureteral cyst and was complicated by calculi formation and inflammatory changes. This case was managed with an open ureterolithotomy with resection of the ureteric cyst and tailoring of the ureter.

Case report

A 37-year-old male presented to the surgical outpatient department with complaints of right lower abdominal pain and fever for one month. The pain in the right lower abdomen was intermittent, and dull. His fever was low-grade, intermittent, and not accompanied with chills. He did not have hypertension or diabetes. His vitals at presentation were blood pressure 110/76 mmHg, pulse 80/min, respiratory rate 15/min and temperature 99.3 °F. The physical exam revealed tenderness in the right lumbar

and umbilical areas. The hematological parameters were hemoglobin 12.6 gm/dL, white blood cells 15,200/ μ L, urea 27 mg/dL, creatinine 0.9 mg/dL and total bilirubin 0.9 mg/dL. A urine culture revealed the growth of *Escherichia coli*.

An abdominal ultrasound revealed that the right kidney was in the umbilical region in a right paramidline location with the hilum directed laterally. Two calculi measuring 2.2 cm and 1.9 cm were noted in the proximal ureter with several small calculi noted in the distal ureter. The left kidney was normal. The patient was further evaluated by computed tomography urography (CTU) which confirmed the abdominal ultrasound findings. Additionally, three separate ureters were noted arising from the calyces of the right kidney draining in a fusiform dilatation of the proximal ureter measuring 4.9x2.5 cm, suggestive of a proximal ureteral cyst (Figure 1). Two large calculi were

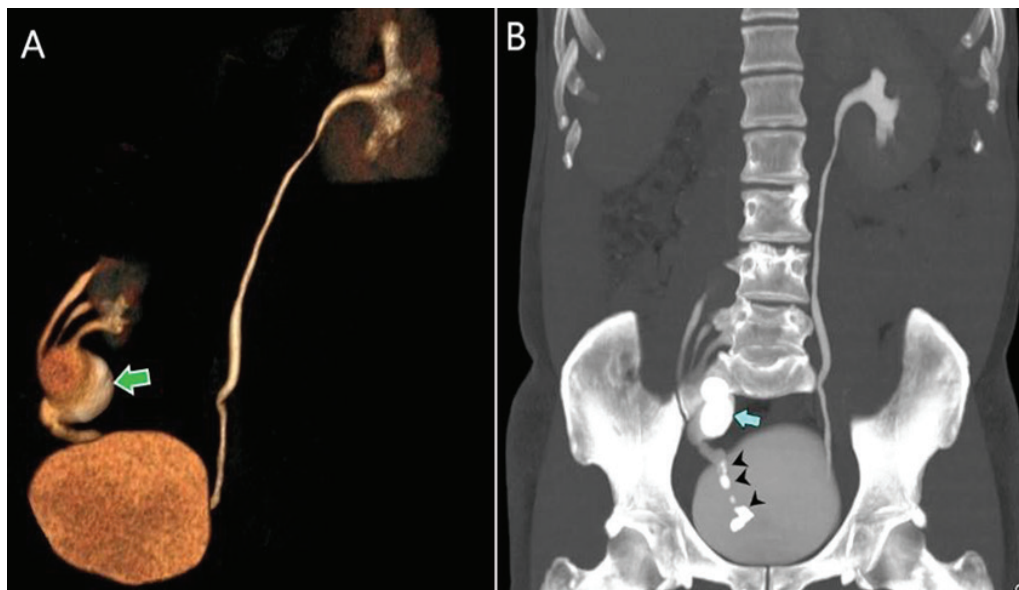


Figure 1 (A) A volume rendered reconstruction image of the computed tomography urography (CTU) showing three ureters arising from the right kidney and draining into a proximal ureteric cyst (green arrow). A distal monoureter is seen arising from the ureteric cyst. (B) A maximum intensity projection image of the CTU in the excretory phase showing two large calculi within the ureteral cyst (blue arrow) and multiple small calculi within the distal monoureter (arrowheads).

noted within the ureteral cyst. These calculi were smaller than the maximum diameter of the cystic dilatation. A distal monoureter was noted arising from the ureteral cyst and the cystic–distal ureteric junction was non–obstructed. The distal ureter was studded with multiple small calculi. The collecting system of the right kidney was not dilated. The walls of the proximal ureteral cyst demonstrated enhancement after contrast administration with associated adjacent areas of fat stranding suggestive of ongoing inflammation (Figure 2A). Both kidneys demonstrated prompt uptake and excretion of intravenous contrast.

The patient was initially stabilized with a course of antibiotics. He subsequently underwent an open ureterolithotomy with resection of the ureteral cyst and reconstruction of the ureter. The ureteral cyst was incised and the calculi evacuated. The patch around the three openings of the proximal ureters was anastomosed with the

patch around the single distal ureter and the cyst between them was resected. Two large calculi were evacuated from the ureteric cyst and multiple calculi from the distal ureter (Figure 2B). Complete evacuation of the distal ureteric calculi was confirmed by an intraoperative ureterogram. A double–J catheter was placed in situ. Postoperatively, the patient had an uneventful recovery with complete relief of his symptoms. A urine culture showed no growth on follow up and the patient was doing well 4 months after the surgery.

Discussion

A triplicate ureter is an uncommon congenital urinary system malformation that arises from the Wolffian duct during the fifth week of embryological development. After four weeks of development, the distal section of the Wolffian duct gives rise to the ureteral bud. During the 6th to 8th weeks of development, the distal end develops into the renal

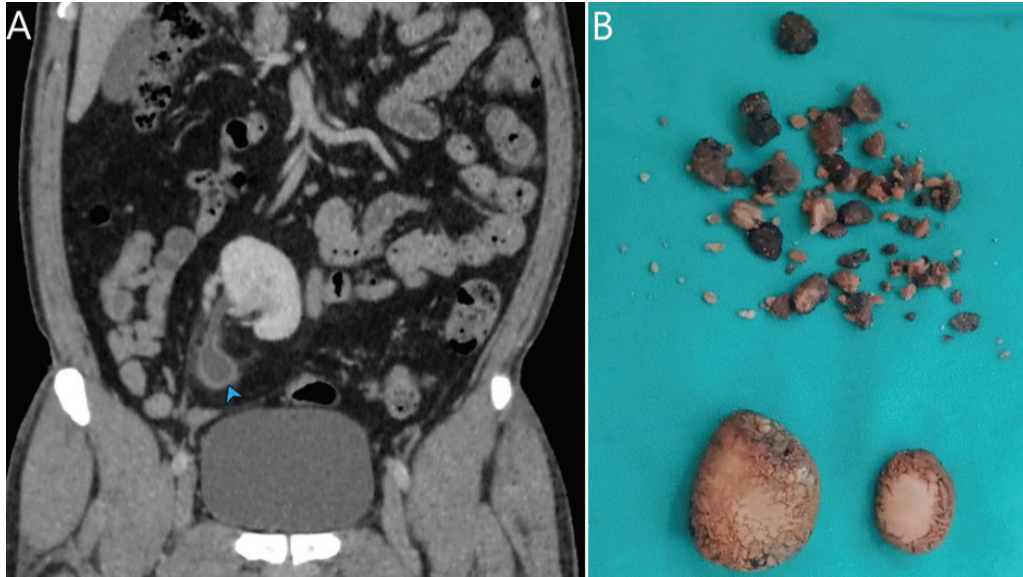


Figure 2 (A) An oblique coronal reconstruction image of the computed tomography urography in the nephrogenic phase showing enhancement of the walls of the ureteral cyst (arrowhead) along with adjacent areas of fat stranding suggestive of inflammatory changes. (B) Gross specimens of two large extracted calculi and multiple smaller distal ureteric calculi.

pelvis and the calyceal system after growing dorsally and then cranially, coming into contact with the metanephros. In a triplicate ureter, three ureteral buds emerge separately from the mesonephric duct or one or more ureteral buds split early to unite with the metanephros⁵.

Ureteral triplication is usually asymptomatic, although it can cause renal colic, urine incontinence or recurrent urinary tract infection episodes and deranged kidney function. Contralateral duplications, ectopic ureteric insertion, renal dysplasia, and vesicoureteral reflux are all frequent urological malformations associated with triplicate ureter^{4,5}. Recurrent urinary infections can be associated with any ureteral abnormality⁶. In our case, the patient had a fever and inflammatory changes were noted in the ureteral cyst on imaging.

Ureteric triplication was classified into four types by Smith in 1946. Type 1, complete triplicate ureters (35% of cases). Type 2- two ureters out of the three join on their way to the urinary bladder and two openings are present in the urinary bladder (21% of cases). Type 3, trifid ureters that join together and drain through a single opening in the bladder (31% of cases), and type 4, double ureters with one of the bifurcations as an inverse Y draining into three orifices (9% of cases). The patient in our case was Type 3⁴.

Ureteral cysts, which are frequently linked with a blind-ending ureter, are an uncommon cause of abdominal cystic lesions. Only 100 similar incidents have so far been documented. Although the exact embryological cause of these cysts is unknown, they may be due to the growth of extra ureteric buds or the inability of a ureteric bud to unite with the metanephros. The age of presentation is determined by the size of the cyst and the presence or absence of complications such as blockage, infection, or hemorrhage⁷.

Any abdominal cystic lesion that is located more laterally instead of the usual central position should raise the possibility of a ureteric cyst over mesenteric cyst.

Also, the presence of further renal or ureteric anomalies should increase the suspicion of the ureteral cyst. An intra-venous pyelogram, for example, may be beneficial in revealing aberrant ureteric architecture or communication of the ureter with the cyst⁷. The features of absence of the upstream hydronephrosis and larger size of the cyst as compared to the calculi favor the diagnosis of ureteral cyst with secondary calculi formation over calculi causing distension of the ureter. In the present case, the cyst was communicating with the ureters and apart from the ureteral cyst, no other ureteral dilatations were seen.

Conclusion

A triplicate ureter with a complicated ureteral cyst is an extremely rare association and is usually without any characteristic presenting symptoms. This entity is to be kept as a possibility in patients with recurrent urinary tract infections or incontinence.

Funding source

None

Conflict of interest

All authors declare no potential conflict of interest.

References

1. Klinge L, Kubiak R, Slongo T. Quadruplication of the ureter in combination with a large ureteral cyst. *Pediatr Surg Int* 2001; 17:566–8.
2. Wahyudi I, Fahri M, Situmorang GR, Rodjani A. Bilateral ureteral triplication: a case report. *Urol Case Rep* 2020;33:101406.
3. Bloom R, Crooks K, Wise H. Complete ureteral triplication with ectopia. *Urology* 1985;25:176–8.
4. Solomon IP, Klein I, Dekel Y. Urosepsis and abscess in an adult with a triplicated renal collecting system treated percutaneously and endoscopically. *Radiol Case Rep* 2022;17:275–8.
5. Xu Z, Li Z, Wang D, Deng G, Su C, Pan J, et al. Ureteral triplication combined with right renal ectopia and ureteral cyst. *Urol Int* 2009;83:476–8.

6. Vicentini FC, Denes FT, Srougi M. Case report: ureteral quadruplication associated with ureteral cyst and massive vesicoureteral reflux treated by laparoscopic nephroureterectomy. *J Endourol* 2007;21:769–71.
7. Awan SR, Corbally MT, Guiney EJ. Ureteric cyst: an unusual abdominal mass. *European J Pediatr Surg* 1993;3:248–9.